

GEORGIAN MEDICAL NEWS

ISSN 1512-0112

NO 3 (372) March 2026

ТБИЛИСИ - NEW YORK



ЕЖЕМЕСЯЧНЫЙ НАУЧНЫЙ ЖУРНАЛ

Медицинские новости Грузии
საქართველოს სამედიცინო სიახლენი

GEORGIAN MEDICAL NEWS

Monthly Georgia-US joint scientific journal published both in electronic and paper formats of the Agency of Medical Information of the Georgian Association of Business Press.
Published since 1994. Distributed in NIS, EU and USA.

GMN: Georgian Medical News is peer-reviewed, published monthly journal committed to promoting the science and art of medicine and the betterment of public health, published by the GMN Editorial Board since 1994. GMN carries original scientific articles on medicine, biology and pharmacy, which are of experimental, theoretical and practical character; publishes original research, reviews, commentaries, editorials, essays, medical news, and correspondence in English and Russian.

GMN is indexed in MEDLINE, SCOPUS, PubMed and VINITI Russian Academy of Sciences. The full text content is available through EBSCO databases.

GMN: Медицинские новости Грузии - ежемесячный рецензируемый научный журнал, издаётся Редакционной коллегией с 1994 года на русском и английском языках в целях поддержки медицинской науки и улучшения здравоохранения. В журнале публикуются оригинальные научные статьи в области медицины, биологии и фармации, статьи обзорного характера, научные сообщения, новости медицины и здравоохранения. Журнал индексируется в MEDLINE, отражён в базе данных SCOPUS, PubMed и ВИНТИ РАН. Полнотекстовые статьи журнала доступны через БД EBSCO.

GMN: Georgian Medical News – საქართველოს სამედიცინო სიახლენი – არის ყოველთვიური სამეცნიერო სამედიცინო რეცენზირებადი ჟურნალი, გამოიცემა 1994 წლიდან, წარმოადგენს სარედაქციო კოლეგიისა და აშშ-ის მეცნიერების, განათლების, ინდუსტრიის, ხელოვნებისა და ბუნებისმეტყველების საერთაშორისო აკადემიის ერთობლივ გამოცემას. GMN-ში რუსულ და ინგლისურ ენებზე ქვეყნდება ექსპერიმენტული, თეორიული და პრაქტიკული ხასიათის ორიგინალური სამეცნიერო სტატიები მედიცინის, ბიოლოგიისა და ფარმაციის სფეროში, მიმოხილვითი ხასიათის სტატიები.

ჟურნალი ინდექსირებულია MEDLINE-ის საერთაშორისო სისტემაში, ასახულია SCOPUS-ის, PubMed-ის და ВИНТИ РАН-ის მონაცემთა ბაზებში. სტატიების სრული ტექსტი ხელმისაწვდომია EBSCO-ს მონაცემთა ბაზებიდან.

WEBSITE

www.geomednews.com

К СВЕДЕНИЮ АВТОРОВ!

При направлении статьи в редакцию необходимо соблюдать следующие правила:

1. Статья должна быть представлена в двух экземплярах, на русском или английском языках, напечатанная через **полтора интервала на одной стороне стандартного листа с шириной левого поля в три сантиметра**. Используемый компьютерный шрифт для текста на русском и английском языках - **Times New Roman (Кириллица)**, для текста на грузинском языке следует использовать **AcadNusx**. Размер шрифта - **12**. К рукописи, напечатанной на компьютере, должен быть приложен CD со статьей.

2. Размер статьи должен быть не менее десяти и не более двадцати страниц машинописи, включая указатель литературы и резюме на английском, русском и грузинском языках.

3. В статье должны быть освещены актуальность данного материала, методы и результаты исследования и их обсуждение.

При представлении в печать научных экспериментальных работ авторы должны указывать вид и количество экспериментальных животных, применявшиеся методы обезболивания и усыпления (в ходе острых опытов).

4. К статье должны быть приложены краткое (на полстраницы) резюме на английском, русском и грузинском языках (включающее следующие разделы: цель исследования, материал и методы, результаты и заключение) и список ключевых слов (key words).

5. Таблицы необходимо представлять в печатной форме. Фотокопии не принимаются. **Все цифровые, итоговые и процентные данные в таблицах должны соответствовать таковым в тексте статьи**. Таблицы и графики должны быть озаглавлены.

6. Фотографии должны быть контрастными, фотокопии с рентгенограмм - в позитивном изображении. Рисунки, чертежи и диаграммы следует озаглавить, пронумеровать и вставить в соответствующее место текста **в tiff формате**.

В подписях к микрофотографиям следует указывать степень увеличения через окуляр или объектив и метод окраски или импрегнации срезов.

7. Фамилии отечественных авторов приводятся в оригинальной транскрипции.

8. При оформлении и направлении статей в журнал МНГ просим авторов соблюдать правила, изложенные в «Единых требованиях к рукописям, представляемым в биомедицинские журналы», принятых Международным комитетом редакторов медицинских журналов - <http://www.spinesurgery.ru/files/publish.pdf> и http://www.nlm.nih.gov/bsd/uniform_requirements.html В конце каждой оригинальной статьи приводится библиографический список. В список литературы включаются все материалы, на которые имеются ссылки в тексте. Список составляется в алфавитном порядке и нумеруется. Литературный источник приводится на языке оригинала. В списке литературы сначала приводятся работы, написанные знаками грузинского алфавита, затем кириллицей и латиницей. Ссылки на цитируемые работы в тексте статьи даются в квадратных скобках в виде номера, соответствующего номеру данной работы в списке литературы. Большинство цитированных источников должны быть за последние 5-7 лет.

9. Для получения права на публикацию статья должна иметь от руководителя работы или учреждения визу и сопроводительное отношение, написанные или напечатанные на бланке и заверенные подписью и печатью.

10. В конце статьи должны быть подписи всех авторов, полностью приведены их фамилии, имена и отчества, указаны служебный и домашний номера телефонов и адреса или иные координаты. Количество авторов (соавторов) не должно превышать пяти человек.

11. Редакция оставляет за собой право сокращать и исправлять статьи. Корректур авторам не высылаются, вся работа и сверка проводится по авторскому оригиналу.

12. Недопустимо направление в редакцию работ, представленных к печати в иных издательствах или опубликованных в других изданиях.

При нарушении указанных правил статьи не рассматриваются.

REQUIREMENTS

Please note, materials submitted to the Editorial Office Staff are supposed to meet the following requirements:

1. Articles must be provided with a double copy, in English or Russian languages and typed or computer-printed on a single side of standard typing paper, with the left margin of 3 centimeters width, and 1.5 spacing between the lines, typeface - **Times New Roman (Cyrillic)**, print size - 12 (referring to Georgian and Russian materials). With computer-printed texts please enclose a CD carrying the same file titled with Latin symbols.

2. Size of the article, including index and resume in English, Russian and Georgian languages must be at least 10 pages and not exceed the limit of 20 pages of typed or computer-printed text.

3. Submitted material must include a coverage of a topical subject, research methods, results, and review.

Authors of the scientific-research works must indicate the number of experimental biological species drawn in, list the employed methods of anesthetization and soporific means used during acute tests.

4. Articles must have a short (half page) abstract in English, Russian and Georgian (including the following sections: aim of study, material and methods, results and conclusions) and a list of key words.

5. Tables must be presented in an original typed or computer-printed form, instead of a photocopied version. **Numbers, totals, percentile data on the tables must coincide with those in the texts of the articles.** Tables and graphs must be headed.

6. Photographs are required to be contrasted and must be submitted with doubles. Please number each photograph with a pencil on its back, indicate author's name, title of the article (short version), and mark out its top and bottom parts. Drawings must be accurate, drafts and diagrams drawn in Indian ink (or black ink). Photocopies of the X-ray photographs must be presented in a positive image in **tiff format**.

Accurately numbered subtitles for each illustration must be listed on a separate sheet of paper. In the subtitles for the microphotographs please indicate the ocular and objective lens magnification power, method of coloring or impregnation of the microscopic sections (preparations).

7. Please indicate last names, first and middle initials of the native authors, present names and initials of the foreign authors in the transcription of the original language, enclose in parenthesis corresponding number under which the author is listed in the reference materials.

8. Please follow guidance offered to authors by The International Committee of Medical Journal Editors guidance in its Uniform Requirements for Manuscripts Submitted to Biomedical Journals publication available online at: http://www.nlm.nih.gov/bsd/uniform_requirements.html
http://www.icmje.org/urm_full.pdf

In GMN style for each work cited in the text, a bibliographic reference is given, and this is located at the end of the article under the title "References". All references cited in the text must be listed. The list of references should be arranged alphabetically and then numbered. References are numbered in the text [numbers in square brackets] and in the reference list and numbers are repeated throughout the text as needed. The bibliographic description is given in the language of publication (citations in Georgian script are followed by Cyrillic and Latin).

9. To obtain the rights of publication articles must be accompanied by a visa from the project instructor or the establishment, where the work has been performed, and a reference letter, both written or typed on a special signed form, certified by a stamp or a seal.

10. Articles must be signed by all of the authors at the end, and they must be provided with a list of full names, office and home phone numbers and addresses or other non-office locations where the authors could be reached. The number of the authors (co-authors) must not exceed the limit of 5 people.

11. Editorial Staff reserves the rights to cut down in size and correct the articles. Proof-sheets are not sent out to the authors. The entire editorial and collation work is performed according to the author's original text.

12. Sending in the works that have already been assigned to the press by other Editorial Staffs or have been printed by other publishers is not permissible.

**Articles that Fail to Meet the Aforementioned
Requirements are not Assigned to be Reviewed.**

ავტორთა საქურაღებოლ!

რედაქციაში სტატიის წარმოდგენისას საჭიროა დაიცვათ შემდეგი წესები:

1. სტატია უნდა წარმოადგინოთ 2 ცალად, რუსულ ან ინგლისურ ენებზე დაბეჭდილი სტანდარტული ფურცლის 1 გვერდზე, 3 სმ სიგანის მარცხენა ველისა და სტრიქონებს შორის 1,5 ინტერვალის დაცვით. გამოყენებული კომპიუტერული შრიფტი რუსულ და ინგლისურენოვან ტექსტებში - **Times New Roman (Кириллица)**, ხოლო ქართულენოვან ტექსტში საჭიროა გამოვიყენოთ **AcadNusx**. შრიფტის ზომა – 12. სტატიას თან უნდა ახლდეს CD სტატიით.

2. სტატიის მოცულობა არ უნდა შეადგენდეს 10 გვერდზე ნაკლებს და 20 გვერდზე მეტს ლიტერატურის სიის და რეზიუმეების (ინგლისურ, რუსულ და ქართულ ენებზე) ჩათვლით.

3. სტატიაში საჭიროა გაშუქდეს: საკითხის აქტუალობა; კვლევის მიზანი; საკვლევი მასალა და გამოყენებული მეთოდები; მიღებული შედეგები და მათი განსჯა. ექსპერიმენტული ხასიათის სტატიების წარმოდგენისას ავტორებმა უნდა მიუთითონ საექსპერიმენტო ცხოველების სახეობა და რაოდენობა; გაუტკივარებისა და დაძინების მეთოდები (მწვავე ცდების პირობებში).

4. სტატიას თან უნდა ახლდეს რეზიუმე ინგლისურ, რუსულ და ქართულ ენებზე არანაკლებ ნახევარი გვერდის მოცულობისა (სათაურის, ავტორების, დაწესებულების მითითებით და უნდა შეიცავდეს შემდეგ განყოფილებებს: მიზანი, მასალა და მეთოდები, შედეგები და დასკვნები; ტექსტუალური ნაწილი არ უნდა იყოს 15 სტრიქონზე ნაკლები) და საკვანძო სიტყვების ჩამონათვალი (key words).

5. ცხრილები საჭიროა წარმოადგინოთ ნაბეჭდი სახით. ყველა ციფრული, შემაჯამებელი და პროცენტული მონაცემები უნდა შეესაბამებოდეს ტექსტში მოყვანილს.

6. ფოტოსურათები უნდა იყოს კონტრასტული; სურათები, ნახაზები, დიაგრამები - დასათაურებული, დანომრილი და სათანადო ადგილას ჩასმული. რენტგენოგრაფიების ფოტოასლები წარმოადგინეთ პოზიტიური გამოსახულებით **tiff** ფორმატში. მიკროფოტოსურათების წარწერებში საჭიროა მიუთითოთ ოკულარის ან ობიექტივის საშუალებით გადიდების ხარისხი, ანათალების შედეგების ან იმპრეგნაციის მეთოდი და აღნიშნოთ სურათის ზედა და ქვედა ნაწილები.

7. სამამულო ავტორების გვარები სტატიაში აღინიშნება ინიციალების თანდართვით, უცხოურისა – უცხოური ტრანსკრიპციით.

8. სტატიას თან უნდა ახლდეს ავტორის მიერ გამოყენებული სამამულო და უცხოური შრომების ბიბლიოგრაფიული სია (ბოლო 5-8 წლის სიღრმით). ანბანური წყობით წარმოდგენილ ბიბლიოგრაფიულ სიაში მიუთითეთ ჯერ სამამულო, შემდეგ უცხოელი ავტორები (გვარი, ინიციალები, სტატიის სათაური, ჟურნალის დასახელება, გამოცემის ადგილი, წელი, ჟურნალის №, პირველი და ბოლო გვერდები). მონოგრაფიის შემთხვევაში მიუთითეთ გამოცემის წელი, ადგილი და გვერდების საერთო რაოდენობა. ტექსტში კვადრატულ ფხიხლებში უნდა მიუთითოთ ავტორის შესაბამისი N ლიტერატურის სიის მიხედვით. მიზანშეწონილია, რომ ციტირებული წყაროების უმეტესი ნაწილი იყოს 5-6 წლის სიღრმის.

9. სტატიას თან უნდა ახლდეს: ა) დაწესებულების ან სამეცნიერო ხელმძღვანელის წარდგინება, დამოწმებული ხელმოწერითა და ბეჭდით; ბ) დარგის სპეციალისტის დამოწმებული რეცენზია, რომელშიც მითითებული იქნება საკითხის აქტუალობა, მასალის საკმაობა, მეთოდის სანდოობა, შედეგების სამეცნიერო-პრაქტიკული მნიშვნელობა.

10. სტატიის ბოლოს საჭიროა ყველა ავტორის ხელმოწერა, რომელთა რაოდენობა არ უნდა აღემატებოდეს 5-ს.

11. რედაქცია იტოვებს უფლებას შეასწოროს სტატია. ტექსტზე მუშაობა და შეჯერება ხდება საავტორო ორიგინალის მიხედვით.

12. დაუშვებელია რედაქციაში ისეთი სტატიის წარდგენა, რომელიც დასაბეჭდად წარდგენილი იყო სხვა რედაქციაში ან გამოქვეყნებული იყო სხვა გამოცემებში.

აღნიშნული წესების დარღვევის შემთხვევაში სტატიები არ განიხილება.

Ketevan Dundua, Iamze Taboridze, Rusudan Kvanchakhadze, Inga Abesadze, Liana Jashi. CORRELATIONS BETWEEN HOMOCYSTEINE AND VITAMIN B12 IN TYPE 2 DIABETES TREATED WITH METFORMIN.....	6-12
Aigerim Abuova, Baglan Abdakhina, Yelvira Omralina, Yekaterina Zueva, Assel Meiramova. DETERMINANTS OF SPINAL ANKYLOSIS IN KAZAKH PATIENTS WITH ANKYLOSING SPONDYLITIS: A CROSS-SECTIONAL STUDY.....	13-20
R. Gvamichava, T. Beruchashvili, M. Kereselidze, N. Ubilava, C. Seniore. KNOWLEDGE AND BEHAVIORAL ATTITUDES OF THE PRIMARY HEALTH CARE PHYSICIANS REGARDING THE NATIONAL CANCER SCREENING PROGRAM IN GEORGIA.....	21-26
Nazgul B. Matkerimova, Khalmurad. S. Akhmedov, Kenesh O. Dzhusupov. TRENDS IN THE PREVALENCE AND GLOBAL BURDEN OF MUSCULOSKELETAL DISEASES AMONG ADULTS: A NARRATIVE LITERATURE REVIEW OF THE PAST 10 YEARS.....	27-39
Ana Carolina González Romero, Josué Andrés Orozco Pilco, Jennifer Ivette Carrillo Becerra, Ariana Estefanía Pujos Agualongo. ANTIMICROBIAL RESISTANCE PROFILE OF BACTERIAL ISOLATES FROM VENTILATOR-ASSOCIATED PNEUMONIA PATIENTS IN AN ECUADORIAN TERTIARY HOSPITAL.....	40-47
Shoira Khusinova, Abdugaffor Gadaev, Khidoyat Rakhimova, Dilshoda Abdukhamidova, Fariza Khalimova. ADHERENCE TO PHARMACOTHERAPY STANDARDS FOR CHRONIC CARDIOVASCULAR AND RESPIRATORY DISEASES AMONG PRIMARY CARE PHYSICIANS IN THE SAMARKAND REGION.....	48-54
Indira Kaibagarova, Aigul Sartayeva. CLINICAL EFFECTIVENESS OF PERSONALIZED NUTRITION IN TYPE 2 DIABETES: A SYSTEMATIC REVIEW.....	55-63
Zaidoon J. Rmaidh, Yasameen Nasih Tawfeeq, Salim J. Khalaf, Entedhar R. sarhat, Elham M. Mahmood. SALIVARY AND SERUM PROTEIN Z, AND β -ARRESTIN-1 AS A NOVEL DIAGNOSTIC MARKER OF PATIENTS WITH DIABETES MELLITUS TYPE 2.....	64-69
Haitao Lin, Jue Zhang, Wenjie Wen, Liang Chen. ELUCIDATING THE THERAPEUTIC MECHANISMS OF GUT MICROBIOTA METABOLITES IN PERIODONTITIS: A NETWORK PHARMACOLOGY APPROACH.....	70-77
Raushan Dosmagambetova, Aigul Tekebayeva, Neila Tankibayeva, Sholpan Dikanbayeva. LIVER CONDITION OF EXPERIMENTAL ANIMALS EXPOSED TO MINE DUST CONTAINING RARE METALS AND NATURAL RADIONUCLIDES.....	78-86
Shima Ibrahim Ali, Maisa Mohamed Elzaki Mohammed, Mohammad Rawashdeh, Riham Almahdi Mohamed Eissa, Malak Nabeel Majeed Alshammari, Julinar Mohamad Khalil agha, Daniah Moaz Kashabash, Mogahid M.A Zidan, Rihab Ali Yousif, Magdy Ali Abdou Gouda, Praveen Kumar, Moawia Gameraddin. WORK-RELATED MUSCULOSKELETAL SYMPTOMS AMONG SONOGRAPHY PRACTITIONERS IN THE UAE: A CROSS-SECTIONAL STUDY.....	87-92
Sanzhar Khalelov, Marat Syzdykbayev, Gulshat Alimkhanova, Andrey Proshunin, Meyerbek Aimagambetov, Jong Woo Choi, Tae Suk Oh. ANALYSIS OF THE EFFECTIVENESS OF SURGICAL METHODS IN THE TREATMENT OF CLEFT PALATE.....	93-108
M. Zhamutashvili, M. Endeladze, N. Jojua, T. Gognadze, M. Akhvlediani, T. Rukhadze, L. Sharvadze, M. Moistsrapishvili, L. Dolidze, V. Lagvilava, G. Gogoladze, K. Nafissi, Z. Sadeghi, N. Kipiani, S. Capey. HEPATITIS B VIRUS (HBV) REACTIVATION IN PATIENTS CO-INFECTED WITH HUMAN IMMUNODEFICIENCY VIRUS: A CASE REPORT.....	109-111
Zufar Bilalov, Madina Rashova, Berik Tuleubayev, Amina Koshanova, Sergey Shmidt, Elmir Jamaleddinov. TREATMENT OF A PATIENT WITH SEVERE HIGH-VOLTAGE ELECTRICAL INJURY: A CLINICAL CASE.....	112-117
Fawaz A. Alassaf, Mohammed N. Abed. ISOTRETINOIN THERAPY AND ITS EFFECT ON BONE HEALTH IN PATIENTS WITH ACNE VULGARIS.....	118-122
Talgat Muminov, Yevgeniya Filippenko, Akhmetzhan Sugraliyev, Shynar Ospanova, Saule Kassenova, Gulstan Yessetova, Anar Rakisheva, Sanzhar Ashimbekov, Axsaula Serikbaeva. QUANTITATIVE CT-BASED PREDICTION OF EARLY FIBROSIS-LIKE LUNG REMODELING IN ACUTE COVID-19: INTEGRATION WITH CLINICAL AND BIOMARKER CORRELATES.....	123-131
Rostomova N.E, Asmalova P.A, Khairoev S.I, Dzhanumova K.G, Dzebisova D.A, Bozhik P.E, Kasich S.O, Kungurova D.L, Rasulov M.N, Cherkasova E.I, Kravtsova A.A, Rutvina I.A, Reutov M.O. COMPARATIVE EFFICACY OF PHENOBARBITAL, FLUMECINOL, AND URSODEOXYCHOLIC ACID IN THE MANAGEMENT OF HYPERBILIRUBINEMIA IN PATIENTS WITH GILBERT SYNDROME: A PROSPECTIVE COMPARATIVE STUDY.....	132-135
Farah NM. AlKhayyat, Intisar K. Farhood, Enas Y. Al-Zubaidy, Haidar S. Ali. IMPACT OF IMPLANT SURFACE ENGINEERING ON OSSEointegration AND FUNCTIONAL STABILITY: A PROSPECTIVE CLINICAL STUDY.....	136-140
Mohamed Abdelhadi, Khaled Aljenaee, Sulaiman Hajji.	

ACUTE CELIAC CRISIS PRESENTING AS SEVERE MALABSORPTIVE DIARRHEA AND HEMODYNAMIC INSTABILITY IN AN ADULT MALE: A CASE REPORT.....	141-143
Tchernev G, Kordeva S, Broshtilova V, Tchernev KG Jr. SECONDARY AMINO GROUPS IN ACE INHIBITORS/ CALCIUM CHANNEL BLOCKERS, ANTIARRHYTHMICS AND ANTICOAGULANTS AS DONORS FOR DRUG RELATED PHOTOTOXICITY/ CARCINOGENICITY EVEN WITHOUT NITROSOCONTAMINATION: THE NUTRITIONAL NITROSOGENESIS AS SUBSTANTIAL/ ADDITIONAL COFACTOR FOR SKIN CARCINOGENESIS AND DONOR FOR PHOTOCARCINOGENS.....	144-152
Shakhista Skenderova, Yerbolat Saruarov, Jubanishbayeva Toizhanay, Nyssantayeva Saltanat, Shakhnoza Tatykayeva. THE ROLE OF SOCIAL DEPRIVATION FACTORS AND QUALITY OF LIFE IN ADULTS WITH METABOLIC SYNDROME: A NARRATIVE REVIEW.....	153-162
Medet Auyenov, Meirbek Aimagambetov, Altai Dyusupov, Ernar Kairkhanov, Assem Kazangapova, Saule Imangazinova, Samatbek Abdrakhmanov, Aldiyar Masalov, Aizat Zhumazhanova, Adlet Auyenov, Daulet Auyenov, Rufat Bakdauletov. A RARE CLINICAL CASE OF A GIANT LIPOMA OF THE RIGHT THIGH.....	163-170
Maysoon Mohammed Hassan, Mohammed Abdulwahab Ati Al-Askeri. INTEGRATED ANALYSIS OF ER α , TP53, AND PGR PROTEINS WITH miR-372, miR-373, AND miR-519D DYSREGULATION IN FEMALE BREAST CANCER.....	171-179
Tinatini Gognadze, Natia Jojua, Tamar Zarginava, Sophio Samkharadze, Lasha Dolidze, Tsisana Giorgadze. MEDICAL PROFESSIONALISM ASSESSMENT AND SELF-EVALUATION PRACTICES AMONG GEORGIAN MEDICAL PRACTITIONERS.....	180-182
T.V. Khorobrykh, V.G. Agadzhanov, D.D. Kadirov, I.V. Ivashov, A.A. Spartak, K.Z. Vagidova, A. Yu. Dorogov, N. O. Kutkin, A.F. Galyautdinov. THE ROLE OF 3D MODELING IN THE SURGICAL MANAGEMENT OF HIATAL HERNIAS: A LITERATURE REVIEW.....	183-194
Medet Auyenov, Meirbek Aimagambetov, Altai Dyusupov, Ernar Kairkhanov, Assem Kazangapova, Saule Imangazinova, Aldiyar Masalov, Samatbek Abdrakhmanov, Aidar Raimkhanov, Nazarbek Omarov, Aizat Zhumazhanova, Sayan Begeldinov. SURGICAL TREATMENT OF OBSTRUCTIVE JAUNDICE IN BENIGN DISEASES OF THE BILIARY TRACT.....	195-204
Rakhimov Anvar, Khalimov Gulom, Khakimova Leyla, Shamsiev Jasur, Yusupov Shukhrat, Khalimova Fariza. GUIDEWIRE-ASSISTED ESOPHAGEAL BOUGIENAGE IN SEVERE CHEMICAL BURNS IN CHILDREN: CLINICAL EFFECTIVENESS OF THE DEVELOPED METHOD.....	205-211
Natia Archaia, Vakhtang Chumburidze, Nona Kakauridze. ANTIPHOSPHOLIPID SYNDROME AS A MODIFIER OF CLINICAL PHENOTYPES IN ATHEROSCLEROTIC CARDIOVASCULAR DISEASE: A CASE-CONTROL STUDY.....	212-219
Nurzhamal Imanbayeva, Khafiza Zhetpisbayeva, Alma Almukhamedova, Galiya Shaimardanova, Karashash Askarova, Nurbek Akazhanov, Nuraiym Orynbaikyzy. WEBER-CHRISTIAN DISEASE: DIAGNOSTIC CHALLENGES AND THERAPEUTIC ADVANCES IN A RARE DISEASE.....	220-225
Aymar Kassa Boukat, Massine El Hammoumi, Yassine Sarboute, El Hassane Kabiri. IATROGENIC PNEUMOTHORAX: ETIOLOGY, CLINICAL AND THERAPEUTIC ASPECTS.....	226-233

LIVER CONDITION OF EXPERIMENTAL ANIMALS EXPOSED TO MINE DUST CONTAINING RARE METALS AND NATURAL RADIONUCLIDES

Raushan Dosmagambetova¹, Aigul Tekebayeva^{2*}, Neila Tankibayeva¹, Sholpan Dikanbayeva².

¹Karaganda Medical University, Gogol St. 40, M01K7G6, Karaganda, Kazakhstan.

²Astana Medical University, Beybitshilik St. 49A, Z10K9D9, Astana, Kazakhstan.

Abstract.

Introduction: Kazakhstan's abundant reserves of non-ferrous and rare metals, which are critical for electronic and digital technologies, orient the country's economy toward the development of the mining industry. The high level of occupational morbidity in the mining and coal industries makes research on the effects of rare metals on detoxification organs particularly relevant.

Aim: The aim of our study was to assess the hepatic detoxification function under the influence of tungsten-molybdenum-polymetallic mine dust containing natural radionuclides in an animal experiment.

Methods: Wistar rats (n = 31) were divided into 2 groups: I – control (n = 11), II – subjected to inhalation exposure to polymetallic dust containing radioactive impurities (n = 20) for 5 months. Biochemical, antioxidant stress, histological, and electron microscopic analyses of liver tissue were performed after 153 days of inhalation exposure to mine dust containing rare metals and natural radionuclides.

Results: In the chronic inhalation effect of mine dust containing rare metals and natural radionuclides on the animal body, the primary mechanism driving pathological changes in the liver is disruption of oxidative processes. A progressive decline in antioxidant enzyme activity under conditions of prolonged exposure to dust and radiation factors increases the risk of structural disorganization of biomembranes and the development of characteristic cellular changes in hepatocytes.

Conclusions: Mine dust containing rare metals and impurities of radioactive substances causes activation of free-radical oxidation processes in animals, impaired cholesterol and oxyproline metabolism in the liver. Under the influence of polymetallic dust, morphological changes characteristic of chronic productive hepatitis develops in the liver tissue, with distinctive features including dystrophic and focal necrotic changes in hepatocytes, a productive tissue reaction of the intralobular and portal stroma, and signs of impaired microcirculation. The results obtained can serve as a basis for the development of preventive measures, taking into account the possible health risks for workers employed in the mining industry.

Key words. Polymetallic mine dust, rare metals, natural radionuclides, peroxidation, hepatocyte.

Introduction.

The largest reserves of non-ferrous and rare metals are concentrated on the territory of Kazakhstan, according to the Concept for the Development of the Geological Industry for 2023-2027, it is envisaged: coverage of the geological

exploration of the territory of Kazakhstan from 94.5% to 100%. An increase in the degree of geological and geophysical exploration of sedimentary basins - developed from 30% to 80%, poorly studied to 10%. Growth of forecast resources: gold - 200 tons; copper - 5 million tons, polymetals - 5 million tons, uranium - 50 thousand tons, hydrocarbons - 700 million tons. It is planned to increase private investment in geological exploration to 800 billion tenge [1-3].

In Kazakhstan, mining enterprises continue to occupy one of the leading places in the development of the country's economy, providing 10-12% of GDP [4]. Modern working conditions at mining enterprises are characterized by elevated dust concentrations, intense noise and vibration, and an unfavorable microclimate, the levels of which frequently exceed established hygiene standards [5,6]. Moreover, even very effective complexes of engineering means of combating harmful production factors do not always ensure a decrease in their levels to acceptable values [7].

Working conditions during underground work, where the effect of adverse production factors on the body of miners is aggravated by psychoemotional loads, lack of sunlight, unfavorable microclimate, limited space during work operations (forced postures), the presence of explosive and soufflard (natural) gases, and the release of radioactive elements, are particularly hazardous and demanding [8,9].

An analysis of occupational morbidity indicators by economic activity sector revealed that a high incidence of occupational disease is noted in the mining industry. Thus, according to the Bureau of National Statistics of the Agency for Strategic Planning and Reforms of the Republic of Kazakhstan in the structure of occupational morbidity, mining and quarrying workers make up 59.3% in 2022, 52.5% in 2023, and 59.3% in 2024 [10].

It is known that when developing mining deposits, metals can enter the body of workers through the respiratory tract and gastrointestinal tract, alveolar macrophages contribute to the movement of xenobiotics in the respiratory tract and further through the pharynx into the digestive tract [11]. According to the IAEA (International Atomic Energy Agency) model, at least 50% of the incoming dust enters the lungs in the first hours and about 12.5% of the dust particles removed from the lungs are also swallowed on the first day. As a result, the total fraction of swallowed particles increases to 62.5%. Thus, the gastrointestinal tract plays a significant role in the ingress of toxic substances into the body of miners. At the same time, the compounds that make up mine dust often have a toxic effect on the morphofunctional state of both the gastrointestinal tract itself and the hepatobiliary system. This fact is confirmed by a

number of clinical studies in which functional changes in the esophagus, stomach and digestive glands were noted in patients with silicosis [12], the presence of silicotic nodules in the liver, kidneys, lungs and lymph nodes was noted in animals receiving oral quartz dust. These data were similar to the changes in the above organs during inhalation experimental silicosis. In this regard, the authors conclude that quartz dust, regardless of the path of penetration into the body (aerogenic or enterogenic), causes a pathological process of the same morphology.

It is generally accepted that one of the main indicators reflecting the influence of production and professional factors on the health status of workers is the incidence of temporary disability. Recent studies on the health status of workers based on an in-depth analysis of the incidence of temporary disability and periodic medical examinations indicate a high incidence of workers involved in the extraction and production of non-ferrous metals [13]. At the same time, workers in contact with molybdenum and tungsten found changes in the digestive system: heartburn, decreased appetite, pain in the epigastric region during palpation. The involvement of the liver in the pathological process is evidenced by the presence of symptoms such as an increase in the size of the organ, tenderness during palpation in the right hypochondrium, impaired antitoxic, protein and glycogen-forming function. This is confirmed by the results of biochemical studies of workers exposed to polymetallic dust. The vast majority of the examined had shifts in protein metabolism: a significant decrease in the content of albumin, albumin-globulin coefficient, an increase in alpha-globulin in blood serum; increase in the level of beta-lipoproteins, cholesterol, and with a load test with galactose - an increase in the glycemic coefficient with a slowdown in the return of the glycemic curve to the initial level. The effect of rare earth elements on the synthesis of procoagulants by the liver was noted, which led to a violation of blood clotting, a decrease in the intensity and rate of blood filling of liver vessels compared to the control.

Given that world technological progress is inextricably linked with the extraction of rare earth metals, it seems relevant to study the effect of polymetallic mine dust containing natural radionuclides in an animal experiment, followed by taking into account possible health risks for workers employed in the mining industry.

The aim of our study was to assess hepatic detoxification function under the influence of tungsten-molybdenum-polymetallic mine dust containing natural radionuclides in an animal experiment.

Materials and Methods.

Experimental design:

In order to study the effect of polymetallic dust containing natural radionuclides, an experimental study was carried out on male rats of the Wistar breed with an average body weight of animals of 140-160 g (about 5–6 weeks old).

In our study, we investigated the effects of akchatau tungsten-molybdenum polymetallic mine dust. The results of chemical analysis and semi-quantitative spectral analysis of the laboratory of the production geological association «Centrkazgeologiya»

in Karaganda indicate a high content of 74.3% silicon dioxide, the content of rare and rare earth metals (Tables 1 and 2).

According to the results of gamma-spectrometric analysis, the effective total activity of akchatau polymetallic mine dust is 314-322 Bq/kg. An increased content of uranium and thorium is determined in the ore, during the alpha decay of which radon gas is formed.

Inhalation dusting with polymetallic dust:

The experimental study was performed in accordance with the international rules and regulations for the treatment of laboratory animals, not contradicting the Geneva Convention of 1985 on «International Principles of Biomedical Research Using Animals». All treatments with animals were approved by Protocol No. 7 of 01.04.2025 by the Local Bioethics Commission of Karaganda Medical University. Chronic inhalation dusting of animals was performed in dust inoculation chambers according to the method of L.B. Borisova, L.B. Mareeva, R.S. Dosmagambetova, A.M. Tekebayeva et al. [14].

Inhalation-dynamic exposure was carried out for 5 hours 5 days a week for 5 months in cylindrical chambers, the animals were placed in individual bottles with extracameral placement. The average dust concentration in the chamber was 50 mg/m³, with an average mass median aerodynamic particle diameter of 50 µm. The concentration of dust in the chamber was controlled by the weighing method.

The inhalation method has a number of advantages: 1) it is a fully physiological method, since the protective role of the upper respiratory tract remains, which is especially important in modeling dust pathology; 2) changes in internal organs due to inhalation priming are closer to those characteristic of similar diseases in humans; 3) inhalation exposure makes it possible to simultaneously detect general toxic and fibrogenic exposure property of polymetallic dusts.

We used a camera to carry out dust seeding, which allows us to conduct research, ensuring a uniform concentration of dust in the breathing zone. The requirements of the aerodynamic distribution of dust particles are to the greatest extent met by cylindrical chambers that allow creating optimal aerodynamic conditions for the distribution of dust flow, and the installation of the diffuser and the design of the upper cover - stable concentrations of dust in the zone of animal respiration. To obtain a stable level of concentration and eliminate the large range of its oscillations, we used a metering device that allows spraying polymetallic dust and maintaining the desired concentration at a constant level.

Animal groups: Wistar rats (n = 31) were divided into 2 groups: I - control, animals were placed in a similar chamber for a time corresponding to dusting, without scattering dust (n = 11), II - subjected to inhalation dusting with polymetallic dust containing impurities of radioactive substances (n = 20) for 5 months.

Biochemical analysis: The intensity of POL processes was determined in liver tissue, which was assessed by the accumulation of primary products - diene conjugate (DC) with conjugated double bonds. During peroxidation, at the stage of free radical formation, a system of conjugated double bonds arises in the molecules of polyunsaturated higher fatty acids.

Table 1. Chemical analysis of akchatau tungsten-molybdenum polymetallic mine dust.

Compound	Content %%	Compound	Content %%
SiO ₂	74,3	MgO	0,74
Al ₂ O ₃	9,8	TiO ₂	0,30
Fe ₂ O ₃	4,6	CO ₂	0,25
K ₂ O	2,8	MnO	0,08
CaO	1,9	WO ₃	0,08
FeO	1,8	P ₂ O ₅	0,06
Na ₂ O	1,5	MO	0,04

Table 2. Semi-quantitative spectral analysis of akchatau tungsten-molybdenum polymetallic mine dust.

Elements	Content g/kg	Elements	Content g/kg	Elements	Content g/kg
Titanium	2,5	Zirconium	0,15	Yttrium	0,025
Barium	1,0	Beryllium	0,12	Halium	0,015
Phosphorus	0,8	Zinc	0,10	Niobium	0,015
Manganese	0,8	Copper	0,06	Scandium	0,012
Tungsten	0,5	Vanadium	0,05	Nickel	0,008
Lead	0,4	Bismuth	0,05	Germanium	0,004
Molybdenum	0,3	Chromium	0,04	Ytterbium	0,0025
Strontium	0,3	Tin	0,03	Silver	0,0008
Lithium	0,2	Cobalt	0,02	-	-

Table 3. Status of POL-AOC Processes in Rat Liver Tissue Dusted with Polymetallic Dust Containing Natural Radionuclides.

Biochemical parameters	Control group (n=11)	Dust group 5 months (n=20)	p-value
DC, rel. units	3.83±1.21	8.18±2.11	p < 0.05
TBC-AP mM/g protein	10.98±3.46	36.30±9.38	p < 0.01
GPO, mm NADPH min/g	246.20±77.80	123.50±32.60	p < 0.05
SOD, unit act/mg of protein	8.52±2.68	1.92±0.49	p < 0.01
Catalase, mM/sec 2/g protein	388.10±122.60	121.00±31.20	p < 0.05

Table 4. Change in cholesterol and oxyproline levels in liver tissue of rats exposed to dusting with polymetallic dust containing natural radionuclides.

Biochemical parameters	Control group (n=11)	Dust group 5 months (n=20)	p-value
Cholesterol, μM/g	14.21±1.67	24.82±3.83	p < 0.02
Hydroxyproline, μg/100mg dry tissue	398.70±12.80	467.50±21.40	p < 0.02

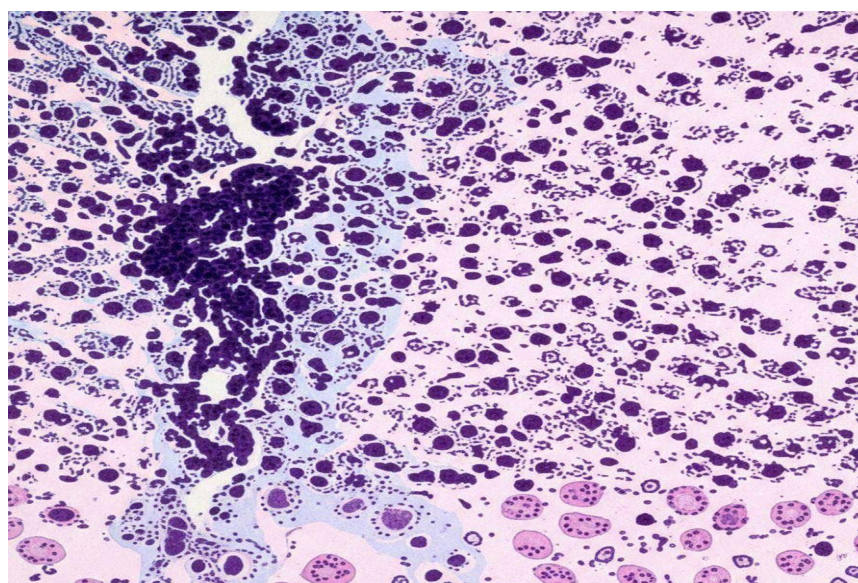


Figure 1. Portal stroma, represented by infiltration by round-cell elements and macrophages. Hematoxylin and eosin staining, scale bar = 50 μm.

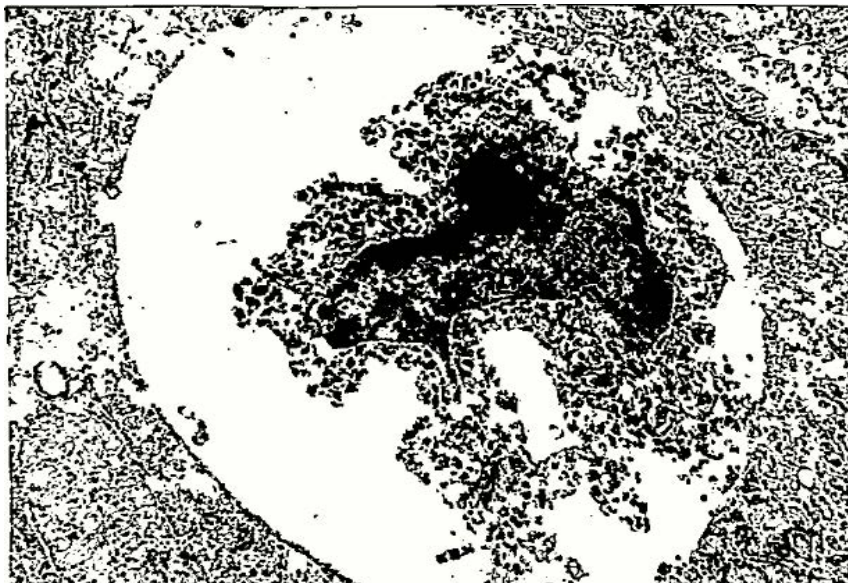


Figure 2. Councilman bodies. Electronogram x21500.

The level of secondary POL products capable of forming colored complexes with thiobarbituric acid (TBC-AP) was determined by a method based on the ability of a part of the lipid peroxidation products belonging to the class of endoperoxides to decompose in an acidic environment and at high temperature to form compounds capable of reacting with thiobarbituric acid to form a colored trimethine complex.

The liver tissue was also evaluated for the state of the AOZ enzymatic link of the body. Glutathione peroxidase (GPO) activity was recorded by the loss of glutathione with peroxide as substrate, and the amount of enzyme required to oxidize 1 micromole of glutathione in 1 mg of protein was taken as a unit of activity.

Superoxide dismutase (SOD) activities by the method based on the ability of the enzyme to compete with nitrosine tetrazolium for superoxide radical anions formed as a result of the aerobic interaction of nicotinamide adenine dinucleotide (NADH) and phenazine metasulfate. Sodium hydroxide was added to the samples to increase the sensitivity of the method.

Catalase activity was determined by a method based on the ability of hydrogen peroxide to form a stable-colored complex with molybdenum salts.

Cholesterol synthesis was assessed by measuring its accumulation in liver tissue homogenate, using a method based on the ability of cholesterol to form a stable-colored complex with the Liebermann-Burchard reagent, with results expressed as micromoles per gram of tissue.

Tissue oxyproline content was determined by oxidizing oxyproline to a compound close to pyrrole and then condensing the compound with p- (dimethylamino) benzaldehyde to form a stably colored complex.

Histology: For histological examination, liver tissue was fixed in a 10% neutral formalin solution, then embedded in paraffin using a conventional procedure. Sections 5-7 μ m thick were stained with hematoxylin and eosin.

Electron microscopic examination. For electron microscopic examination, organ tissue pieces were placed in 2.5%

glutaraldehyde solution on Millonig phosphate buffer pH 7.2-7.4. Additionally, the material was fixed for two hours in a buffered 1% osmium tetroxide solution, dehydrated in alcohols of increasing strength and poured into a mixture of epon and araldite.

Statistical studies: Statistical analyses were performed using IBM SPSS Statistics v.26.0. Categorical variables are presented as absolute and relative frequencies (%), and continuous variables as mean \pm standard deviation. Differences between groups were assessed using the χ^2 test or Student's t-test, depending on distribution.

Results.

The results of the experiment showed that prolonged exposure to polymetallic mine dust causes hyperperoxidation syndrome in animals, as evidenced by the excessive formation of liver lipid membrane peroxidation products.

There was a significant increase in both primary (DC) and secondary (TBC-AP) metabolites of POL, 2.13 ($p < 0.05$) and 3.3 ($p < 0.01$) times, respectively, in the liver in relation to similar control parameters. The predominance of accumulation of secondary highly reactive products indicates a pronounced increasing nature of violation of free radical processes in animals exposed to mine dust containing natural radionuclides.

Also, the data obtained by us indicate that the activity of SOD decreases in the liver by 4.3 times. Catalase is 2.5-fold inactivated in the liver. At the same time, the activity of GPO, the substrate of which is fatty acid hydroperoxides and hydrogen peroxide, is reduced in the liver by 2 times.

The results of the experiment showed that in the group of animals exposed to polymetallic mine dust, a significant increase in the level of hydroxyproline and cholesterol in the homogenate of liver tissue was found. Thus, in the liver, the cholesterol content in animals of the experimental group increased by 74% at $t = 2.54$ ($p < 0.01$) compared to the control group.

The interaction of xenobiotics with the body is accompanied by damage and death of tissue elements, proliferation of fibroblasts

and an increase in the number of collagen-producing cells. The content of hydroxyproline, which reflects tissue sclerosis processes, in the group of animals exposed to chronic inhalation exposure to mine dust in the liver was increased by 1.2 times at $t = 2.76$ ($p < 0.01$) compared to the control level.

In order to more fully assess and objectify the effect of polymetallic mine dust containing natural radionuclides on the animal body, we considered it necessary to use morphological research methods.

Microscopic changes in the liver tissue of rats of the control group on day 153 correspond to age-related changes. The structure of the tissue is unchanged.

Microscopic examination of the liver tissue of rats subjected to inhalation dusting with polymetallic mine dust for 5 months shows pronounced inflammatory changes in the portal stroma, represented by infiltration by round-cell elements and macrophages, which are accompanied by increased sclerotic processes. The vessels of the portal tracts are full-blooded, while hyalinosis of the artery walls is noted, they are concentrically thickened, their lumen is narrowed. Experimental animals develop signs of impaired microcirculation, as evidenced by the deposition of collagen fibers at the sinusoidal pole of individual hepatocytes, that is, there is capillarization of sinusoids. Some hepatic cells in the periportal sections of the hepatic lobules are in a state of intracellular regeneration, binuclear hepatocytes are found, while the round shape of the hepatocyte nucleus is characterized by a dispersed chromatin distribution (Figure 1).

Ultramicroscopic examination of the liver showed that most hepatocytes contain light nuclei with even nuclear envelope contours and reduced chromatin content. The tubules of the granular endoplasmic reticulum are randomly arranged and are characterized by the shedding of fixed ribosomes, pronounced destruction of membranes with the formation of disintegrating and fuzzy fragments. Many mitochondria are characterized by destruction with complete breakdown of mitochondrial membranes. The number of free ribosomes and polysomes in the hyaloplasm is reduced. Individual hepatic cells are in a state of partial collicative necrosis. Councilman bodies are rarely found, with pronounced pycnosis of the nucleus and «mummification» of organelles (Figure 2).

Discussion.

The revealed significant activation of POL processes with prolonged exposure to the body of polymetallic mine dust is apparently explained by its strong membranotoxic effect, leading to disruption of membranes, both cellular and subcellular. It can be thought that when entering the body, dust generates reactive forms and, due to its strong oxidizing capacity, produces active oxygen metabolites with the initiating property of POL [15]. So, in the process of stimulation, hepatic macrophages begin to produce and release activated oxygen species into the medium, while reactive oxygen metabolites initiate POL in the membranes of sinusoid liver cells and can damage them [16].

In addition, free radical processes are further activated by the products of radiolysis of natural radionuclides of the uranium-radium and thorium series. Activation of the processes of POL membranes leads to an increase in their microviscosity, whereby oxidized chains of unsaturated fatty acids migrate to the surface

layer of the membranes while unsaturated hydrocarbon chains remain within the interior, resulting in increased membrane microviscosity.

However, in our studies, we did not quantify the degree of accumulation of heavy metals and radionuclides in liver tissue (ICP-MS), and these pathological changes in liver tissue were not considered as effects from systemic exposure or direct accumulation in the liver.

When animals are exposed to Akchatau tungsten-molybdenum-polymetallic mine dust, the harmful effects are compounded by ionizing radiation, which, in addition to suppressing phagocyte function (manifested in our studies as Kupffer cell blockade), also promotes the formation of free radicals. Radioinduced processes caused by radioactive impurities included in the studied dust, in our opinion, significantly modify the biological effects of polymetallic aerosol, further burdening the processes of peroxidation.

Under conditions of activation of lipoperoxidation processes, the state of the antioxidant system for protecting the integrity of cell membranes is of particular interest. The balance between the POL and AOC systems is maintained until, under conditions of continued exposure to the harmful factor, the rate of peroxide formation exceeds the detoxification capacity of the antioxidant systems [17].

As the results of the study show, under the influence of polymetallic mine dust, free-radical processes intensify in animals against a background of a general decline in antioxidant enzyme activity, which undoubtedly increases the imbalance and contributes to an even greater accumulation of POL products.

Analyzing the data obtained, it can be assumed that the direct, destructive effect of active oxygen intermediates during oxidative phagocytosis of polymetallic dust particles on the active centers of these enzymes cannot be excluded from the mechanism of reducing the activity of antioxidant enzymes. In addition, in reducing the activity of antioxidant enzymes, free-radical damage to synthesis systems can also be important under conditions of prolonged increase in peroxidation [18]. Furthermore, beyond the radiolysis processes characteristic of free unsaturated fatty acids and protozoan membrane formations, ionizing radiation in biomembranes can also suppress protective systems at various levels [19,20].

The various levels of decrease in antioxidant enzyme activity identified during the experiment, in our opinion, can be explained as follows. Given that high levels of SOD are observed in the liver, such a significant inactivation of this enzyme seems to be associated with the predominant formation of a superoxide radical anion during biotransformation of dust particles during oxidative phagocytosis. Some parallelism in the change in the activity of GPO and catalase, noted in our work, is possibly associated with the conjugate nature of the action of enzymes - both enzymes constitute an anti-peroxide line of defense.

Thus, with the chronic inhalation effect of polymetallic mine dust containing natural radionuclides on the animal body, the leading link in the development of pathological changes in the liver is a violation of oxidative processes. An increased drop in the level of enzymes of the antioxidant protection system under conditions of prolonged exposure to dust and radiation factors

increases the risk of structural disorganization of biomembranes.

Similarly to what we found during the experiment, increased cholesterol synthesis and hepatic accumulation are also observed against the background of exposure to industrial toxins [21,22]. At the same time, the process of cholesterol accumulation is always accompanied by the activation of free radical oxidation of lipids with the accumulation of its toxic products. This phenomenon can be explained by the fact that the key enzyme that oxidizes cholesterol in liver microsomes is cholesterol 7- α -hydroxylase, which is an isoform of cytochrome P-450. Production toxins, damaging cell membranes and thereby inhibiting the functions of liver microsomal enzymes, lead to a decrease in cholesterol-7- α -hydroxylase activity. As a result, there is an accumulation of cholesterol, triglycerides and a decrease in phospholipids in the membrane, which is accompanied by an increase in microviscosity of the membranes and the activation of POL processes [23,24].

At the same time, it is known that cholesterol metabolism is a sensitive link in metabolism when exposed to foreign substances, under the influence of toxic compounds, cholesterol accumulates, which is accompanied by a decrease in the permeability of plasma membranes in various tissues and can serve as one of the characteristic signs of the development of sclerotic changes in organs and tissues [25,26].

Thus, the increase in cholesterol found by us in the liver tissues of animals exposed to inhalation exposure to mine dust indicates the development of sclerotic processes.

The biochemical changes obtained by us are confirmed at the ultrastructural level: a decrease in the amount of nuclear chromatin, the number of ribosomes in the hyaloplasm, a sharp destruction of the elements of the granular endoplasmic reticulum reflect a decrease in the processes of synthesis of specific and plastic proteins, a sharp decrease in the total protein due to its decay. The absence of agranular endoplasmic reticulum and glycogen vesicles indicates a pronounced decrease in antitoxic and glycogen-forming liver function. Submicroscopic features of mitochondria partially reflect the compensatory-adaptive reaction of providing the remaining organelles with energy. Fibrous changes develop in the form of capillarization of sinusoids and remote fibrillogenesis, reflecting the transition of the process to a chronic stage. Possibly, blockade of the Kupffer cells of the reticuloendothelial system of the liver develops. Colliquative and coagulative necrosis of individual hepatic cells has been observed.

It should be noted that the liver plays a major role in the metabolism of compounds entering the human and animal body and their neutralization. In the development of toxic liver injuries, two main pathogenetic mechanisms should be distinguished: specific, associated with the realization of its detoxifying function, and non-specific, related to the participation of the liver in maintaining homeostasis under stressful conditions [27-29]. By regulating blood chemistry, the liver, together with the lungs, is involved in the regulation of gas exchange processes. At the same time, liver pathology exerts a significant influence on pulmonary ventilation and acid-base balance. For example, in chronic liver diseases, metabolic acidosis is detected, associated with the accumulation of pyruvic

and lactic acids and tricarboxylic acids of the Krebs cycle in the blood. In response to metabolic acidosis, patients develop compensatory hyperventilation aimed at excreting carbonic acid and, as a result, respiratory alkalosis develops. Evidence in the literature indicates that changes accompanied by functional ventilation-perfusion disorders of the air-blood barrier are detected in the lungs in chronic liver diseases – including an increase in respiratory rate and minute respiratory volume, and a reduction in maximum ventilation, pneumotachometry, airflow velocity, and vital capacity [30,31]. At the same time, patients with combined pulmonary-hepatic pathology require longer inpatient treatment; the author attributes this to the fact that this category of patients presents with more profound immunological disorders compared to those with isolated pathology. The inclusion of hepatoprotective agents (hepatrin, karsil, heptral, essentielle, and others) in the therapeutic regimen improves the clinical course of chronic non-specific lung diseases.

Conclusion.

Mine dust containing rare metals and impurities of radioactive substances causes activation of free-radical oxidation processes in animals, impaired cholesterol and oxyproline metabolism in the liver. Under the influence of polymetallic dust, morphological changes characteristic of chronic productive hepatitis develops in the liver tissue, with distinctive features including dystrophic and focal necrotic changes in hepatocytes, a productive tissue reaction of the intralobular and portal stroma, and signs of impaired microcirculation.

The data we obtained during the experiment on animals on the effect of mine dust containing rare metals and natural radionuclides on the state of such a detoxification organ as the liver enable a better understanding of the pathological changes occurring in the bodies of miners. These findings allow for the development of personalized protection programs, taking into account the possible health risks for workers in the mining industry.

Declaration of Conflict of Interest.

The author (s) declare no clear and potential conflicts of interest related to the publication of this article.

Financing.

The author (s) did not receive financial support for research, authorship, and/or publication of this article.

ORCID iDs.

Raushan Dosmagambetova ORCID ID 0009-0008-1391-553X

Aigul Tekebayeva ORCID ID 0009-0005-5015-8206

Neila Tankibayeva ORCID ID 0000-0002-7432-6535

Sholpan Dikanbayeva ORCID ID 0009-0007-4173-8449

Data Availability Statement.

All data obtained or analyzed during this study are included in the published article.

REFERENCES

1. Kalra P, Shin B, Saxena SS. Critical minerals and the shaping of Central Asian economies through the ages. *Energy Research & Social Science*. 2026;31:104507.

2. Decree of the Government of the Republic of Kazakhstan dated December 30, 2022 No. 1127. Concept for the development of the geological industry in the Republic of Kazakhstan for 2023-2027.
3. Ministry of Industry and Construction of the Republic of Kazakhstan. Geological exploration. <https://www.gov.kz/memleket/entities/mps/activities/34083?lang=ru>
4. Bureau of National Statistics of the Agency for Strategic Planning and Reforms of the Republic of Kazakhstan. <https://stat.gov.kz/ru/industries/economy/national-accounts/>
5. Goryaev D.V, Fadeev A.G, Shur P.Z, et al. Hygienic assessment of working conditions and occupational incidence among mining workers in the arctic zone of the norilsk industrial area. *Health Risk Analysis*. 2023;2:88-94.
6. Lynch H.N, Allen L.H, Hamaji CM, et al. Strategies for refinement of occupational inhalation exposure evaluation in the EPA TSCA risk evaluation process. *Toxicology and Industrial Health*. 2023;39:169-182.
7. Ismailova A.A, Musina A.A, Suleimenova R.K, et al. Comprehensive hygienic assessment of the working conditions of miners engaged in underground polymetallic ore mining. *Perm Medical Journal*. 2024;41:151-159.
8. Volz J.B, Geibert W, Köhler D, et al. Alpha radiation from polymetallic nodules and potential health risks from deep-sea mining. *Sci Rep*. 2023;13:7985.
9. Tripathi R.M, Sahoo S.K, Jha V.N, et al. Assessment of environmental radioactivity at uranium mining, processing and tailings management facility at Jaduguda, India. *Applied Radiation and Isotopes*. 2008;66:1666-1670.
10. BNS. Bulletin: series 17 Labour and employment statistics. Number of employees employed in harmful and other adverse working conditions in the Republic of Kazakhstan; 2022.
11. Damian P. A Literature Review of the Health and Ecological Effects of the Rare Earth Elements. Sacramento; 2014.
12. Zaitseva N.V, Ustinova O.Yu, Alekseev V.B, et al. Peculiarities of production-related diseases in miners employed at deep mining of chromic ores. *Russian Journal of Occupational Health and Industrial Ecology*. 2018;10:6-12.
13. Fomin A.I, Grunskoy T.V. Analytical review of occupational morbidity cases in underground mineral mining on the Komi Republic territory. *Bulletin of the Scientific Center for the Safety of Work in the Coal Industry*. 2021;4:45-54.
14. Borisova L.B, Mareeva L.B, Dosmagambetova R.S, et al. Inhalation priming of animals with dust in a toxicological experiment. *Methodological recommendations*. Almaty; 1997:17.
15. Geraets L, Oomen A.G, Schroeter J.D, et al. Tissue distribution of inhaled micro- and nano-sized cerium oxide particles in rats: results from a 28-day exposure study. *Toxicol. Sci*. 2012;127:463-73.
16. Moldogazieva N.T, Mokhosoev I.M, Melnikova T.I. The dual nature of reactive oxygen, nitrogen and halogen species: their endogenous sources, interconversions and methods of neutralization. *Advances in biological chemistry*. 2020;60:123-172.
17. Zaitseva N.V, Zemlyanova M.A, Stepankov M.S, et al. Experimental study of the mechanism of action and comparative assessment of the toxicity of zinc-containing nano- and microparticles under subacute inhalation exposure. *Hygiene and Sanitation*. 2025;104:1349-1355.
18. Kostyuk SV, Proskurnina EV, Konkova MS, et al. Effect of lowdose ionizing radiation on the expression of mitochondriarelated genes in human mesenchymal stem cells. *Int J Mol Sci*. 2022;23:261.
19. Klaus R, Niyazi M, Lange-Sperandio B. Radiation-induced kidney toxicity: molecular and cellular pathogenesis. *Radiat Oncol*. 2021;16:43.
20. Bellés M, Gonzalo S, Serra N, et al. Environmental exposure to low-doses of ionizing radiation. Effects on early nephrotoxicity in mice. *Environmental Research*. 2017;156:291-296.
21. Li X, Chen Z, Chen Z, et al. A human health risk assessment of rare earth elements in soil and vegetables from a mining area in Fujian Province, Southeast China. *Chemosphere*. 2013;93:1240-6.
22. Pagano G, Thomas P.J, Di Nunzio A, et al. Human exposures to rare earth elements: Present knowledge and research prospects. *Environ. Res*. 2019;171:493-500.
23. Wang C, Luo X, Tian Y, et al. Biphasic effects of lanthanum on *Vicia faba* L. seedlings under cadmium stress, implicating finite antioxidation and potential ecological risk. *Chemosphere*. 2012;86:530-537.
24. Zhao H, Hong J, Yu X, et al. Oxidative stress in the kidney injury of mice following exposure to lanthanides trichloride. *Chemosphere*. 2013;93:875-84.
25. Rim K.T, Koo K.H, Park J.S. Toxicological evaluations of rare earths and their health impacts to workers: a literature review. *Saf. Health Work*. 2013;4:12-26.
26. Pagano G, Guida M, Tommasi F, et al. Health effects and toxicity mechanisms of rare earth elements – Knowledge gaps and research prospects. *Ecotoxicol. Environ. Saf*. 2015;115:40-48.
27. Azab KS, Maarouf RE, Abdel-Rafei MK, et al. *Withania somnifera* (Ashwagandha) root extract counteract acute and chronic impact of γ -radiation on liver and spleen of rats. *Human & Experimental Toxicology*. 2022;41.
28. Abdel-Aziz N, Haroun RA-H, Mohamed HE. Low-Dose Gamma Radiation Modulates Liver and Testis Tissues Response to Acute Whole-Body Irradiation. *Dose-Response*. 2022;20.
29. Abdel-Aziz N, Elkady AA, Elgazzar EM. Effect of low-dose gamma radiation and lipoic acid on high- radiation-dose induced rat brain injuries. *Dose-Response*. 2021;19:1-13.
30. Balali-Mood M, Naseri K, Tahergorabi Z, et al. Toxic mechanisms of five heavy metals: mercury, Lead, chromium, cadmium, and arsenic. *Front Pharmacol*. 2021;12:643972.
31. Zemlyanova M.A, Koldibekova Yu.V, Ukhayrov V.M. The influence of harmful physical factors and industrial dust on changes in some biochemical and functional indicators of the cardiovascular system and respiratory system in workers engaged in underground mining of ore. *Russian Journal of Occupational Health and Industrial Ecology*. 2019;11:920-925.

СОСТОЯНИЕ ПЕЧЕНИ ЭКСПЕРИМЕНТАЛЬНЫХ ЖИВОТНЫХ ПРИ ВОЗДЕЙСТВИИ РУДНИЧНОЙ ПЫЛИ, СОДЕРЖАЩЕЙ РЕДКИЕ МЕТАЛЛЫ И ЕСТЕСТВЕННЫЕ РАДИОНУКЛИДЫ

Рушан Досмагамбетова¹, Айгуль Текебаева^{2*}, Нэйла Танкибаева¹, Шолпан Диканбаева²

¹Карагандинский Медицинский Университет, ул. Гоголя 40, M01K7G6, Караганда, Казахстан.

²Медицинский университет Астана, ул. Бейбитшилик 49А, Z10K9D9, Астана, Казахстан.

Абстракт.

Введение: Ресурсное богатство Казахстана цветными и редкими металлами, являющимися критически важными для электронных и цифровых технологий, предопределяет направление экономики страны в сторону развития горнодобывающей промышленности. Высокий уровень профессиональной заболеваемости в горнорудной и угольной промышленности делает актуальным исследование по изучению влияния редких металлов на органы детоксикации.

Цель: Оценить состояние органа детоксикации печени при воздействии вольфрам-молибден-полиметаллической рудничной пыли, содержащей естественные радионуклиды в эксперименте.

Методы: Крысы породы Wistar (n=31) были поделены на 2 группы: I – контрольная (n=11), II – подвергавшаяся ингаляционному запылению полиметаллической пылью, содержащей примеси радиоактивных веществ (n=20) в течение 5 месяцев. Биохимический анализ, анализ антиоксидантного стресса, гистологические и электронно-микроскопические исследования ткани печени изучали после 153 суток ингаляционного воздействия рудничной пыли, содержащей редкие металлы и естественные радионуклиды.

Результаты: При хроническом ингаляционном воздействии рудничной пыли, содержащей редкие металлы и естественные радионуклиды на организм животных, ведущим звеном в процессе развития патологических изменений в печени является нарушение окислительных процессов. Усиленное падение уровня ферментов антиоксидантной системы защиты в условиях длительного воздействия пылевого и радиационного факторов повышает риск структурной дезорганизации биомембран, развитию характерных клеточных изменений гепатоцитов.

Выводы: Рудничная пыль, содержащая редкие металлы и примеси радиоактивных веществ, вызывает у животных активацию процессов свободно-радикального окисления, нарушения обмена холестерина и оксипролина в печени. Под воздействием полиметаллической пыли в ткани печени развиваются морфологические изменения, характерные для хронического продуктивного гепатита. Отличительными особенностями которого являются дистрофические и очаговые некротические изменения гепатоцитов, продуктивная тканевая реакция внутридольковой и портальной стромы, признаки нарушения микроциркуляции. Полученные результаты, могут послужить основой для разработки превентивных мер с учетом возможных рисков для здоровья рабочих, занятых в горнодобывающей отрасли.

Ключевые слова: полиметаллическая рудничная пыль, редкие металлы, естественные радионуклиды, перекисное окисление, гепатоцит.

ღვიძლის მდგომარეობა ექსპერიმენტულ ცხოველებში,

რომლებიც ექვემდებარებოდნენ იშვიათი ლითონებისა და ბუნებრივი რადიონუკლიდების შემცველი მადაროს მტვრის

რუმან დოსმაგამბეტოვა¹, აიგულ თეკებაევა^{2*}, ნეილა ტანკიბაევა¹,

შოლპან დიკანბაევა²

აბსტრაქტი.

შესავალი: ყაზახეთის ფერადი და იშვიათი ლითონების სიმდიდრე, რომლებიც კრიტიკულად მნიშვნელოვანია ელექტრონული და ციფრული ტექნოლოგიებისთვის, განსაზღვრავს ქვეყნის ეკონომიკურ მიმართულებას სამთო მრეწველობის განვითარებისკენ. სამთო და ქვანახშირის მრეწველობაში პროფესიული დაავადებების მაღალი დონე აქტუალურს ხდის იშვიათი ლითონების დეტოქსიკაციის ორგანოებზე ზემოქმედების კვლევას. მიზანი. ღვიძლის დეტოქსიკაციის ორგანოს მდგომარეობის შეფასება ბუნებრივი რადიონუკლიდების შემცველი ვოლფრამ-მოლიბდენ-პოლიმეტალური მადაროს მტვრის ექსპერიმენტული ზემოქმედებისას.

მეთოდები: ვისტარის ჯიშის ვირთხები (n=31) დაიყვნენ ორ ჯგუფად: I ჯგუფი – საკონტროლო ჯგუფი (n=11), II ჯგუფი – 5 თვის განმავლობაში რადიოაქტიური მინარევების შემცველი პოლიმეტალური მტვრის ინჰალაციის ზემოქმედების ქვეშ (n=20). ღვიძლის ქსოვილის ბიოქიმიური ანალიზი, ანტიოქსიდანტური სტრესის ანალიზი, ჰისტოლოგიური და ელექტრონული მიკროსკოპიული კვლევები შესწავლილ იქნა იშვიათი ლითონებისა და ბუნებრივი რადიონუკლიდების შემცველი მადაროს მტვრის 153-დღიანი ინჰალაციის შემდეგ.

შედეგები: ცხოველებში, რომლებიც ქრონიკულად ექვემდებარებოდნენ იშვიათი ლითონებისა და ბუნებრივი რადიონუკლიდების შემცველი მადაროს მტვრის ინჰალაციის გზით ზემოქმედებას, ღვიძლში პათოლოგიური ცვლილებების განვითარების წამყვანი ფაქტორია ჟანგვითი პროცესების დარღვევა. მტვრისა და რადიაციის ხანგრძლივი ზემოქმედების დროს ანტიოქსიდანტური ფერმენტების დონის მნიშვნელოვანი შემცირება ზრდის ბიომემბრანების სტრუქტურული დისორგანიზაციის და ჰეპატოციტებში დამახასიათებელი უჯრედული ცვლილებების განვითარების რისკს.

დასკვნები: იშვიათი ლითონებისა და რადიოაქტიური მინარევების შემცველი მადაროს მტვერი ცხოველებში ააქტიურებს თავისუფალი რადიკალების დაჟანგვის პროცესებს, რაც არღვევს ქოლესტერინისა და ჰიდროქსიპროლინის მეტაბოლიზმს ღვიძლში. პოლიმეტალური მტვრის ზემოქმედება იწვევს ღვიძლის ქსოვილში მორფოლოგიურ ცვლილებებს, რაც დამახასიათებელია ქრონიკული პროდუქტიული ჰეპატიტისთვის. გამორჩეული ნიშნებია ჰეპატოციტების დეგენერაციული და ფოკალური ნეკროზული ცვლილებები, პროდუქტიული ქსოვილის რეაქციები ინტრალობულურ და პორტალურ სტრომაში და მიკროცირკულაციის დარღვევის ნიშნები. მიღებული შედეგები შეიძლება საფუძვლად დაედო პრევენციული

ზომების შემუშავებას, სამთო მრეწველობაში დასაქმებული მუშაკებისთვის შესაძლო ჯანმრთელობის რისკების გათვალისწინებით.

საკვანძო სიტყვები: პოლიმეტალური მადაროს მტვერი, იშვიათი ლითონები, ბუნებრივი რადიონუკლიდები, პეროქსიდაცია, ჰეპატოციტი.