

GEORGIAN MEDICAL NEWS

ISSN 1512-0112

NO 3 (372) March 2026

ТБИЛИСИ - NEW YORK



ЕЖЕМЕСЯЧНЫЙ НАУЧНЫЙ ЖУРНАЛ

Медицинские новости Грузии
საქართველოს სამედიცინო სიახლენი

GEORGIAN MEDICAL NEWS

Monthly Georgia-US joint scientific journal published both in electronic and paper formats of the Agency of Medical Information of the Georgian Association of Business Press.
Published since 1994. Distributed in NIS, EU and USA.

GMN: Georgian Medical News is peer-reviewed, published monthly journal committed to promoting the science and art of medicine and the betterment of public health, published by the GMN Editorial Board since 1994. GMN carries original scientific articles on medicine, biology and pharmacy, which are of experimental, theoretical and practical character; publishes original research, reviews, commentaries, editorials, essays, medical news, and correspondence in English and Russian.

GMN is indexed in MEDLINE, SCOPUS, PubMed and VINITI Russian Academy of Sciences. The full text content is available through EBSCO databases.

GMN: Медицинские новости Грузии - ежемесячный рецензируемый научный журнал, издаётся Редакционной коллегией с 1994 года на русском и английском языках в целях поддержки медицинской науки и улучшения здравоохранения. В журнале публикуются оригинальные научные статьи в области медицины, биологии и фармации, статьи обзорного характера, научные сообщения, новости медицины и здравоохранения. Журнал индексируется в MEDLINE, отражён в базе данных SCOPUS, PubMed и ВИНТИ РАН. Полнотекстовые статьи журнала доступны через БД EBSCO.

GMN: Georgian Medical News – საქართველოს სამედიცინო სიახლენი – არის ყოველთვიური სამეცნიერო სამედიცინო რეცენზირებადი ჟურნალი, გამოიცემა 1994 წლიდან, წარმოადგენს სარედაქციო კოლეგიისა და აშშ-ის მეცნიერების, განათლების, ინდუსტრიის, ხელოვნებისა და ბუნებისმეტყველების საერთაშორისო აკადემიის ერთობლივ გამოცემას. GMN-ში რუსულ და ინგლისურ ენებზე ქვეყნდება ექსპერიმენტული, თეორიული და პრაქტიკული ხასიათის ორიგინალური სამეცნიერო სტატიები მედიცინის, ბიოლოგიისა და ფარმაციის სფეროში, მიმოხილვითი ხასიათის სტატიები.

ჟურნალი ინდექსირებულია MEDLINE-ის საერთაშორისო სისტემაში, ასახულია SCOPUS-ის, PubMed-ის და ВИНТИ РАН-ის მონაცემთა ბაზებში. სტატიების სრული ტექსტი ხელმისაწვდომია EBSCO-ს მონაცემთა ბაზებშიდან.

WEBSITE

www.geomednews.com

К СВЕДЕНИЮ АВТОРОВ!

При направлении статьи в редакцию необходимо соблюдать следующие правила:

1. Статья должна быть представлена в двух экземплярах, на русском или английском языках, напечатанная через **полтора интервала на одной стороне стандартного листа с шириной левого поля в три сантиметра**. Используемый компьютерный шрифт для текста на русском и английском языках - **Times New Roman (Кириллица)**, для текста на грузинском языке следует использовать **AcadNusx**. Размер шрифта - **12**. К рукописи, напечатанной на компьютере, должен быть приложен CD со статьей.

2. Размер статьи должен быть не менее десяти и не более двадцати страниц машинописи, включая указатель литературы и резюме на английском, русском и грузинском языках.

3. В статье должны быть освещены актуальность данного материала, методы и результаты исследования и их обсуждение.

При представлении в печать научных экспериментальных работ авторы должны указывать вид и количество экспериментальных животных, применявшиеся методы обезболивания и усыпления (в ходе острых опытов).

4. К статье должны быть приложены краткое (на полстраницы) резюме на английском, русском и грузинском языках (включающее следующие разделы: цель исследования, материал и методы, результаты и заключение) и список ключевых слов (key words).

5. Таблицы необходимо представлять в печатной форме. Фотокопии не принимаются. **Все цифровые, итоговые и процентные данные в таблицах должны соответствовать таковым в тексте статьи**. Таблицы и графики должны быть озаглавлены.

6. Фотографии должны быть контрастными, фотокопии с рентгенограмм - в позитивном изображении. Рисунки, чертежи и диаграммы следует озаглавить, пронумеровать и вставить в соответствующее место текста **в tiff формате**.

В подписях к микрофотографиям следует указывать степень увеличения через окуляр или объектив и метод окраски или импрегнации срезов.

7. Фамилии отечественных авторов приводятся в оригинальной транскрипции.

8. При оформлении и направлении статей в журнал МНГ просим авторов соблюдать правила, изложенные в «Единых требованиях к рукописям, представляемым в биомедицинские журналы», принятых Международным комитетом редакторов медицинских журналов - <http://www.spinesurgery.ru/files/publish.pdf> и http://www.nlm.nih.gov/bsd/uniform_requirements.html В конце каждой оригинальной статьи приводится библиографический список. В список литературы включаются все материалы, на которые имеются ссылки в тексте. Список составляется в алфавитном порядке и нумеруется. Литературный источник приводится на языке оригинала. В списке литературы сначала приводятся работы, написанные знаками грузинского алфавита, затем кириллицей и латиницей. Ссылки на цитируемые работы в тексте статьи даются в квадратных скобках в виде номера, соответствующего номеру данной работы в списке литературы. Большинство цитированных источников должны быть за последние 5-7 лет.

9. Для получения права на публикацию статья должна иметь от руководителя работы или учреждения визу и сопроводительное отношение, написанные или напечатанные на бланке и заверенные подписью и печатью.

10. В конце статьи должны быть подписи всех авторов, полностью приведены их фамилии, имена и отчества, указаны служебный и домашний номера телефонов и адреса или иные координаты. Количество авторов (соавторов) не должно превышать пяти человек.

11. Редакция оставляет за собой право сокращать и исправлять статьи. Корректур авторам не высылаются, вся работа и сверка проводится по авторскому оригиналу.

12. Недопустимо направление в редакцию работ, представленных к печати в иных издательствах или опубликованных в других изданиях.

При нарушении указанных правил статьи не рассматриваются.

REQUIREMENTS

Please note, materials submitted to the Editorial Office Staff are supposed to meet the following requirements:

1. Articles must be provided with a double copy, in English or Russian languages and typed or computer-printed on a single side of standard typing paper, with the left margin of 3 centimeters width, and 1.5 spacing between the lines, typeface - **Times New Roman (Cyrillic)**, print size - 12 (referring to Georgian and Russian materials). With computer-printed texts please enclose a CD carrying the same file titled with Latin symbols.

2. Size of the article, including index and resume in English, Russian and Georgian languages must be at least 10 pages and not exceed the limit of 20 pages of typed or computer-printed text.

3. Submitted material must include a coverage of a topical subject, research methods, results, and review.

Authors of the scientific-research works must indicate the number of experimental biological species drawn in, list the employed methods of anesthetization and soporific means used during acute tests.

4. Articles must have a short (half page) abstract in English, Russian and Georgian (including the following sections: aim of study, material and methods, results and conclusions) and a list of key words.

5. Tables must be presented in an original typed or computer-printed form, instead of a photocopied version. **Numbers, totals, percentile data on the tables must coincide with those in the texts of the articles.** Tables and graphs must be headed.

6. Photographs are required to be contrasted and must be submitted with doubles. Please number each photograph with a pencil on its back, indicate author's name, title of the article (short version), and mark out its top and bottom parts. Drawings must be accurate, drafts and diagrams drawn in Indian ink (or black ink). Photocopies of the X-ray photographs must be presented in a positive image in **tiff format**.

Accurately numbered subtitles for each illustration must be listed on a separate sheet of paper. In the subtitles for the microphotographs please indicate the ocular and objective lens magnification power, method of coloring or impregnation of the microscopic sections (preparations).

7. Please indicate last names, first and middle initials of the native authors, present names and initials of the foreign authors in the transcription of the original language, enclose in parenthesis corresponding number under which the author is listed in the reference materials.

8. Please follow guidance offered to authors by The International Committee of Medical Journal Editors guidance in its Uniform Requirements for Manuscripts Submitted to Biomedical Journals publication available online at: http://www.nlm.nih.gov/bsd/uniform_requirements.html
http://www.icmje.org/urm_full.pdf

In GMN style for each work cited in the text, a bibliographic reference is given, and this is located at the end of the article under the title "References". All references cited in the text must be listed. The list of references should be arranged alphabetically and then numbered. References are numbered in the text [numbers in square brackets] and in the reference list and numbers are repeated throughout the text as needed. The bibliographic description is given in the language of publication (citations in Georgian script are followed by Cyrillic and Latin).

9. To obtain the rights of publication articles must be accompanied by a visa from the project instructor or the establishment, where the work has been performed, and a reference letter, both written or typed on a special signed form, certified by a stamp or a seal.

10. Articles must be signed by all of the authors at the end, and they must be provided with a list of full names, office and home phone numbers and addresses or other non-office locations where the authors could be reached. The number of the authors (co-authors) must not exceed the limit of 5 people.

11. Editorial Staff reserves the rights to cut down in size and correct the articles. Proof-sheets are not sent out to the authors. The entire editorial and collation work is performed according to the author's original text.

12. Sending in the works that have already been assigned to the press by other Editorial Staffs or have been printed by other publishers is not permissible.

**Articles that Fail to Meet the Aforementioned
Requirements are not Assigned to be Reviewed.**

ავტორთა საქურაღებოლ!

რედაქციაში სტატიის წარმოდგენისას საჭიროა დაიცვათ შემდეგი წესები:

1. სტატია უნდა წარმოადგინოთ 2 ცალად, რუსულ ან ინგლისურ ენებზე დაბეჭდილი სტანდარტული ფურცლის 1 გვერდზე, 3 სმ სიგანის მარცხენა ველისა და სტრიქონებს შორის 1,5 ინტერვალის დაცვით. გამოყენებული კომპიუტერული შრიფტი რუსულ და ინგლისურენოვან ტექსტებში - **Times New Roman (Кириллица)**, ხოლო ქართულენოვან ტექსტში საჭიროა გამოვიყენოთ **AcadNusx**. შრიფტის ზომა – 12. სტატიას თან უნდა ახლდეს CD სტატიით.

2. სტატიის მოცულობა არ უნდა შეადგენდეს 10 გვერდზე ნაკლებს და 20 გვერდზე მეტს ლიტერატურის სიის და რეზიუმეების (ინგლისურ, რუსულ და ქართულ ენებზე) ჩათვლით.

3. სტატიაში საჭიროა გაშუქდეს: საკითხის აქტუალობა; კვლევის მიზანი; საკვლევი მასალა და გამოყენებული მეთოდები; მიღებული შედეგები და მათი განსჯა. ექსპერიმენტული ხასიათის სტატიების წარმოდგენისას ავტორებმა უნდა მიუთითონ საექსპერიმენტო ცხოველების სახეობა და რაოდენობა; გაუტკივარებისა და დაძინების მეთოდები (მწვავე ცდების პირობებში).

4. სტატიას თან უნდა ახლდეს რეზიუმე ინგლისურ, რუსულ და ქართულ ენებზე არანაკლებ ნახევარი გვერდის მოცულობისა (სათაურის, ავტორების, დაწესებულების მითითებით და უნდა შეიცავდეს შემდეგ განყოფილებებს: მიზანი, მასალა და მეთოდები, შედეგები და დასკვნები; ტექსტუალური ნაწილი არ უნდა იყოს 15 სტრიქონზე ნაკლები) და საკვანძო სიტყვების ჩამონათვალი (key words).

5. ცხრილები საჭიროა წარმოადგინოთ ნაბეჭდი სახით. ყველა ციფრული, შემაჯამებელი და პროცენტული მონაცემები უნდა შეესაბამებოდეს ტექსტში მოყვანილს.

6. ფოტოსურათები უნდა იყოს კონტრასტული; სურათები, ნახაზები, დიაგრამები - დასათაურებული, დანომრილი და სათანადო ადგილას ჩასმული. რენტგენოგრამების ფოტოასლები წარმოადგინეთ პოზიტიური გამოსახულებით **tiff** ფორმატში. მიკროფოტოსურათების წარწერებში საჭიროა მიუთითოთ ოკულარის ან ობიექტივის საშუალებით გადიდების ხარისხი, ანათალების შედეგების ან იმპრეგნაციის მეთოდი და აღნიშნოთ სურათის ზედა და ქვედა ნაწილები.

7. სამამულო ავტორების გვარები სტატიაში აღინიშნება ინიციალების თანდართვით, უცხოურისა – უცხოური ტრანსკრიპციით.

8. სტატიას თან უნდა ახლდეს ავტორის მიერ გამოყენებული სამამულო და უცხოური შრომების ბიბლიოგრაფიული სია (ბოლო 5-8 წლის სიღრმით). ანბანური წყობით წარმოდგენილ ბიბლიოგრაფიულ სიაში მიუთითეთ ჯერ სამამულო, შემდეგ უცხოელი ავტორები (გვარი, ინიციალები, სტატიის სათაური, ჟურნალის დასახელება, გამოცემის ადგილი, წელი, ჟურნალის №, პირველი და ბოლო გვერდები). მონოგრაფიის შემთხვევაში მიუთითეთ გამოცემის წელი, ადგილი და გვერდების საერთო რაოდენობა. ტექსტში კვადრატულ ფხიხლებში უნდა მიუთითოთ ავტორის შესაბამისი N ლიტერატურის სიის მიხედვით. მიზანშეწონილია, რომ ციტირებული წყაროების უმეტესი ნაწილი იყოს 5-6 წლის სიღრმის.

9. სტატიას თან უნდა ახლდეს: ა) დაწესებულების ან სამეცნიერო ხელმძღვანელის წარდგინება, დამოწმებული ხელმოწერითა და ბეჭდით; ბ) დარგის სპეციალისტის დამოწმებული რეცენზია, რომელშიც მითითებული იქნება საკითხის აქტუალობა, მასალის საკმაობა, მეთოდის სანდოობა, შედეგების სამეცნიერო-პრაქტიკული მნიშვნელობა.

10. სტატიის ბოლოს საჭიროა ყველა ავტორის ხელმოწერა, რომელთა რაოდენობა არ უნდა აღემატებოდეს 5-ს.

11. რედაქცია იტოვებს უფლებას შეასწოროს სტატია. ტექსტზე მუშაობა და შეჯერება ხდება საავტორო ორიგინალის მიხედვით.

12. დაუშვებელია რედაქციაში ისეთი სტატიის წარდგენა, რომელიც დასაბეჭდად წარდგენილი იყო სხვა რედაქციაში ან გამოქვეყნებული იყო სხვა გამოცემებში.

აღნიშნული წესების დარღვევის შემთხვევაში სტატიები არ განიხილება.

Ketevan Dundua, Iamze Taboridze, Rusudan Kvanchakhadze, Inga Abesadze, Liana Jashi. CORRELATIONS BETWEEN HOMOCYSTEINE AND VITAMIN B12 IN TYPE 2 DIABETES TREATED WITH METFORMIN.....	6-12
Aigerim Abuova, Baglan Abdakhina, Yelvira Omralina, Yekaterina Zueva, Assel Meiramova. DETERMINANTS OF SPINAL ANKYLOSIS IN KAZAKH PATIENTS WITH ANKYLOSING SPONDYLITIS: A CROSS-SECTIONAL STUDY.....	13-20
R. Gvamichava, T. Beruchashvili, M. Kereselidze, N. Ubilava, C. Seniore. KNOWLEDGE AND BEHAVIORAL ATTITUDES OF THE PRIMARY HEALTH CARE PHYSICIANS REGARDING THE NATIONAL CANCER SCREENING PROGRAM IN GEORGIA.....	21-26
Nazgul B. Matkerimova, Khalmurad. S. Akhmedov, Kenesh O. Dzhusupov. TRENDS IN THE PREVALENCE AND GLOBAL BURDEN OF MUSCULOSKELETAL DISEASES AMONG ADULTS: A NARRATIVE LITERATURE REVIEW OF THE PAST 10 YEARS.....	27-39
Ana Carolina González Romero, Josué Andrés Orozco Pilco, Jennifer Ivette Carrillo Becerra, Ariana Estefanía Pujos Agualongo. ANTIMICROBIAL RESISTANCE PROFILE OF BACTERIAL ISOLATES FROM VENTILATOR-ASSOCIATED PNEUMONIA PATIENTS IN AN ECUADORIAN TERTIARY HOSPITAL.....	40-47
Shoira Khusinova, Abdugaffor Gadaev, Khidoyat Rakhimova, Dilshoda Abdukhamidova, Fariza Khalimova. ADHERENCE TO PHARMACOTHERAPY STANDARDS FOR CHRONIC CARDIOVASCULAR AND RESPIRATORY DISEASES AMONG PRIMARY CARE PHYSICIANS IN THE SAMARKAND REGION.....	48-54
Indira Kaibagarova, Aigul Sartayeva. CLINICAL EFFECTIVENESS OF PERSONALIZED NUTRITION IN TYPE 2 DIABETES: A SYSTEMATIC REVIEW.....	55-63
Zaidoon J. Rmaidh, Yasameen Nasih Tawfeeq, Salim J. Khalaf, Entedhar R. sarhat, Elham M. Mahmood. SALIVARY AND SERUM PROTEIN Z, AND β -ARRESTIN-1 AS A NOVEL DIAGNOSTIC MARKER OF PATIENTS WITH DIABETES MELLITUS TYPE 2.....	64-69
Haitao Lin, Jue Zhang, Wenjie Wen, Liang Chen. ELUCIDATING THE THERAPEUTIC MECHANISMS OF GUT MICROBIOTA METABOLITES IN PERIODONTITIS: A NETWORK PHARMACOLOGY APPROACH.....	70-77
Raushan Dosmagambetova, Aigul Tekebayeva, Neila Tankibayeva, Sholpan Dikanbayeva. LIVER CONDITION OF EXPERIMENTAL ANIMALS EXPOSED TO MINE DUST CONTAINING RARE METALS AND NATURAL RADIONUCLIDES.....	78-86
Shima Ibrahim Ali, Maisa Mohamed Elzaki Mohammed, Mohammad Rawashdeh, Riham Almahdi Mohamed Eissa, Malak Nabeel Majeed Alshammari, Julinar Mohamad Khalil agha, Daniah Moaz Kashabash, Mogahid M.A Zidan, Rihab Ali Yousif, Magdy Ali Abdou Gouda, Praveen Kumar, Moawia Gameraddin. WORK-RELATED MUSCULOSKELETAL SYMPTOMS AMONG SONOGRAPHY PRACTITIONERS IN THE UAE: A CROSS-SECTIONAL STUDY.....	87-92
Sanzhar Khalelov, Marat Syzdykbayev, Gulshat Alimkhanova, Andrey Proshunin, Meyerbek Aimagambetov, Jong Woo Choi, Tae Suk Oh. ANALYSIS OF THE EFFECTIVENESS OF SURGICAL METHODS IN THE TREATMENT OF CLEFT PALATE.....	93-108
M. Zhamutashvili, M. Endeladze, N. Jojua, T. Gognadze, M. Akhvlediani, T. Rukhadze, L. Sharvadze, M. Moistsrapishvili, L. Dolidze, V. Lagvilava, G. Gogoladze, K. Nafissi, Z. Sadeghi, N. Kipiani, S. Capey. HEPATITIS B VIRUS (HBV) REACTIVATION IN PATIENTS CO-INFECTED WITH HUMAN IMMUNODEFICIENCY VIRUS: A CASE REPORT.....	109-111
Zufar Bilalov, Madina Rashova, Berik Tuleubayev, Amina Koshanova, Sergey Shmidt, Elmir Jamaleddinov. TREATMENT OF A PATIENT WITH SEVERE HIGH-VOLTAGE ELECTRICAL INJURY: A CLINICAL CASE.....	112-117
Fawaz A. Alassaf, Mohammed N. Abed. ISOTRETINOIN THERAPY AND ITS EFFECT ON BONE HEALTH IN PATIENTS WITH ACNE VULGARIS.....	118-122
Talgat Muminov, Yevgeniya Filippenko, Akhmetzhan Sugraliyev, Shynar Ospanova, Saule Kassenova, Gulstan Yessetova, Anar Rakisheva, Sanzhar Ashimbekov, Axsaula Serikbaeva. QUANTITATIVE CT-BASED PREDICTION OF EARLY FIBROSIS-LIKE LUNG REMODELING IN ACUTE COVID-19: INTEGRATION WITH CLINICAL AND BIOMARKER CORRELATES.....	123-131
Rostomova N.E, Asmalova P.A, Khairoev S.I, Dzhanumova K.G, Dzebisova D.A, Bozhik P.E, Kasich S.O, Kungurova D.L, Rasulov M.N, Cherkasova E.I, Kravtsova A.A, Rutvina I.A, Reutov M.O. COMPARATIVE EFFICACY OF PHENOBARBITAL, FLUMECINOL, AND URSODEOXYCHOLIC ACID IN THE MANAGEMENT OF HYPERBILIRUBINEMIA IN PATIENTS WITH GILBERT SYNDROME: A PROSPECTIVE COMPARATIVE STUDY.....	132-135
Farah NM. AlKhayyat, Intisar K. Farhood, Enas Y. Al-Zubaidy, Haidar S. Ali. IMPACT OF IMPLANT SURFACE ENGINEERING ON OSSEointegration AND FUNCTIONAL STABILITY: A PROSPECTIVE CLINICAL STUDY.....	136-140
Mohamed Abdelhadi, Khaled Aljenaee, Sulaiman Hajji.	

ACUTE CELIAC CRISIS PRESENTING AS SEVERE MALABSORPTIVE DIARRHEA AND HEMODYNAMIC INSTABILITY IN AN ADULT MALE: A CASE REPORT.....	141-143
Tchernev G, Kordeva S, Broshtilova V, Tchernev KG Jr. SECONDARY AMINO GROUPS IN ACE INHIBITORS/ CALCIUM CHANNEL BLOCKERS, ANTIARRHYTHMICS AND ANTICOAGULANTS AS DONORS FOR DRUG RELATED PHOTOTOXICITY/ CARCINOGENICITY EVEN WITHOUT NITROSOCONTAMINATION: THE NUTRITIONAL NITROSOGENESIS AS SUBSTANTIAL/ ADDITIONAL COFACTOR FOR SKIN CARCINOGENESIS AND DONOR FOR PHOTOCARCINOGENS.....	144-152
Shakhista Skenderova, Yerbolat Saruarov, Jubanishbayeva Toizhanay, Nyssantayeva Saltanat, Shakhnoza Tatykayeva. THE ROLE OF SOCIAL DEPRIVATION FACTORS AND QUALITY OF LIFE IN ADULTS WITH METABOLIC SYNDROME: A NARRATIVE REVIEW.....	153-162
Medet Auyenov, Meirbek Aimagambetov, Altai Dyusupov, Ernar Kairkhanov, Assem Kazangapova, Saule Imangazinova, Samatbek Abdrakhmanov, Aldiyar Masalov, Aizat Zhumazhanova, Adlet Auyenov, Daulet Auyenov, Rufat Bakdauletov. A RARE CLINICAL CASE OF A GIANT LIPOMA OF THE RIGHT THIGH.....	163-170
Maysoon Mohammed Hassan, Mohammed Abdulwahab Ati Al-Askeri. INTEGRATED ANALYSIS OF ER α , TP53, AND PGR PROTEINS WITH miR-372, miR-373, AND miR-519D DYSREGULATION IN FEMALE BREAST CANCER.....	171-179
Tinatini Gognadze, Natia Jojua, Tamar Zarginava, Sophio Samkharadze, Lasha Dolidze, Tsisana Giorgadze. MEDICAL PROFESSIONALISM ASSESSMENT AND SELF-EVALUATION PRACTICES AMONG GEORGIAN MEDICAL PRACTITIONERS.....	180-182
T.V. Khorobrykh, V.G. Agadzhanov, D.D. Kadirov, I.V. Ivashov, A.A. Spartak, K.Z. Vagidova, A. Yu. Dorogov, N. O. Kutkin, A.F. Galyautdinov. THE ROLE OF 3D MODELING IN THE SURGICAL MANAGEMENT OF HIATAL HERNIAS: A LITERATURE REVIEW.....	183-194
Medet Auyenov, Meirbek Aimagambetov, Altai Dyusupov, Ernar Kairkhanov, Assem Kazangapova, Saule Imangazinova, Aldiyar Masalov, Samatbek Abdrakhmanov, Aidar Raimkhanov, Nazarbek Omarov, Aizat Zhumazhanova, Sayan Begeldinov. SURGICAL TREATMENT OF OBSTRUCTIVE JAUNDICE IN BENIGN DISEASES OF THE BILIARY TRACT.....	195-204
Rakhimov Anvar, Khalimov Gulom, Khakimova Leyla, Shamsiev Jasur, Yusupov Shukhrat, Khalimova Fariza. GUIDEWIRE-ASSISTED ESOPHAGEAL BOUGIENAGE IN SEVERE CHEMICAL BURNS IN CHILDREN: CLINICAL EFFECTIVENESS OF THE DEVELOPED METHOD.....	205-211
Natia Archaia, Vakhtang Chumburidze, Nona Kakauridze. ANTIPHOSPHOLIPID SYNDROME AS A MODIFIER OF CLINICAL PHENOTYPES IN ATHEROSCLEROTIC CARDIOVASCULAR DISEASE: A CASE-CONTROL STUDY.....	212-219
Nurzhamal Imanbayeva, Khafiza Zhetpisbayeva, Alma Almukhamedova, Galiya Shaimardanova, Karashash Askarova, Nurbek Akazhanov, Nuraiym Orynbaikyzy. WEBER-CHRISTIAN DISEASE: DIAGNOSTIC CHALLENGES AND THERAPEUTIC ADVANCES IN A RARE DISEASE.....	220-225
Aymar Kassa Boukat, Massine El Hammoumi, Yassine Sarboute, El Hassane Kabiri. IATROGENIC PNEUMOTHORAX: ETIOLOGY, CLINICAL AND THERAPEUTIC ASPECTS.....	226-233

TREATMENT OF A PATIENT WITH SEVERE HIGH-VOLTAGE ELECTRICAL INJURY: A CLINICAL CASE

Zufar Bilalov^{1,2}, Madina Rashova², Berik Tuleubayev^{1,2}, Amina Koshanova^{1,2*}, Sergey Shmidt¹, Elmir Jamaleddinov^{1,2}.

¹Department of Surgical Diseases, "Karaganda Medical University", Karaganda, Kazakhstan,

²Department of Biomedicine, "Karaganda Medical University", Karaganda, Kazakhstan

³Regional Center of Traumatology and Orthopedics named after prof. Kh. Zh. Makazhanov, Karaganda, Kazakhstan

Abstract.

A 32-year-old patient sustained a high-voltage electrical injury while touching live parts of railway equipment. Examination revealed electrical burns of mixed depth covering a total area of 42%, 25% of which were deep grade IIIB burns. The affected area included the face, neck, torso, and right extremities. The Frank burn index was 92 units, consistent with an extremely severe burn injury. Laboratory tests revealed a pronounced systemic inflammatory response, hypoproteinemia, signs of metabolic stress, and activated coagulation. Bilateral lower lobe pneumonia and retinal angiopathy were also diagnosed. The patient received intensive fluid, antibacterial, and analgesic therapy. Local wound care and vital signs were monitored daily. Six staged surgeries were performed—a series of necrectomy procedures on October 15, 20, 22, 24, 28, and 31, 2025—aimed at removing necrotic tissue, reducing the toxic load, and preventing the development of infectious complications. Against the background of complex treatment, positive clinical dynamics, stabilization of laboratory parameters and improvement of the condition of burn wounds were noted, which made it possible to proceed to the stage of closing the defect from the received burn injuries, which took place on 13.11.2025. This case demonstrates that successful treatment of high-voltage electrical burns is only possible with early intensive care, sequential surgical interventions, and ongoing monitoring for metabolic and infectious complications.

Key words. Electrical injury, electrical burn, burn shock, autodermplasty, alloblast.

Introduction.

Electrical injuries are a type of trauma resulting from human interaction with electric current, whether low or high voltage, resulting in damage or complete dysfunction of tissues or organs [1]. Electrical injuries are becoming an increasingly pressing problem due to daily scientific and technological progress. Two categories of electrical injuries are discussed: low-voltage and high-voltage [2]. Globally, 1.2 million electrical injuries occur annually, of which low-voltage electrical injuries account for <1-3% of fatalities, while high-voltage electrical injuries account for <5-30% [3].

High-voltage electrical injuries are among the most severe types of burn pathology and are accompanied by profound tissue destruction, severe microcirculatory disturbances, and pronounced systemic metabolic reactions [4]. Unlike contact thermal burns, high-voltage electric current causes not only superficial and deep skin damage but also affects other body systems, including deep necrosis of muscles, blood vessels, and nerves due to the current's passage through the body. These injuries are characterized by a high mortality rate, a high incidence of burn shock, generalized toxemia, and cardiovascular and respiratory complications, requiring early, multi-stage surgical intervention and intensive care. This clinical case illustrates the complex nature of managing a patient with high-

energy electrical injury and emphasizes the importance of timely diagnosis and a multidisciplinary approach.

Clinical Case.

A 32-year-old patient sustained an electrical injury while attempting to walk over a railway car on 10.10.2025 around 20:30. The injury was work-related and involved contact with live parts of the rolling stock. As a result, he received a high-voltage electric shock and lost consciousness at the time of the injury. According to the patient, he regained consciousness in the hospital. He was taken from the scene to the emergency room of the Agadyr Central Hospital and admitted to the intensive care unit. Diagnosis on admission: Electrical injury. Burn disease. Electrical injury. IIIA–IIIB degree electrical burns of the face, neck, right upper extremity, chest, anterior abdominal wall, and right lower extremity covering 42% (IIIB 25%). Frank index 92 units. Severe burn shock. After stabilization, on 12.10.25, he was transported by air ambulance, accompanied by an ambulance team, to the emergency room of the Multidisciplinary Hospital named after Professor Kh. Zh. Makazhan. He was hospitalized in the Combustiology Department on an emergency basis.

Status presents: General condition of moderate severity due to the injury sustained. Conscious and adequate. Oriented to time and place. Skin outside the burn wounds is normal in color. Breathing sounds are harsh, without wheezing. Respiratory rate is 19 per minute. Heart sounds are clear and rhythmic. Blood pressure is 120/80 mmHg; PS is 75 per minute. The tongue is clean and moist. The abdomen is soft and painless on palpation and participates in respiration. Diuresis is through a urinary catheter, urine is yellow.

St. Localis: Upon examination, burn wounds are present on the face, neck, right upper limb, back, and extending to the lateral

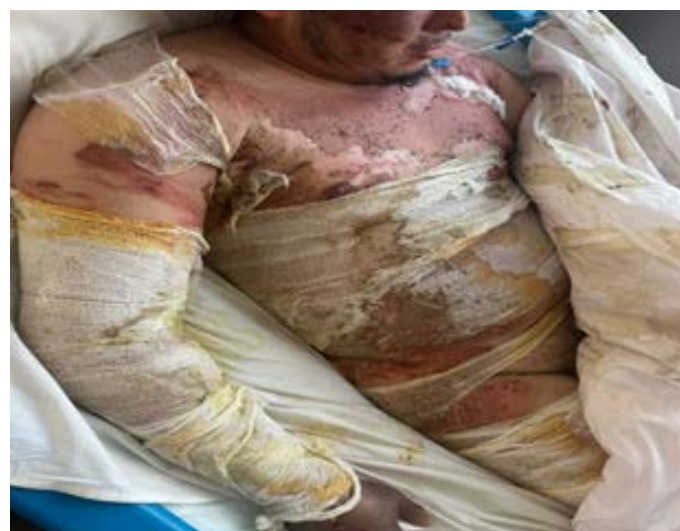
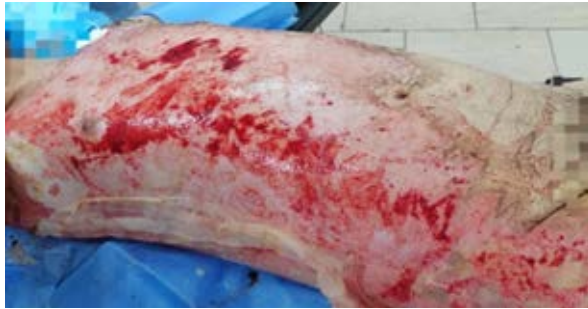
Figure 1. The first 24 hours after admission.



Chest with a transition to the lateral surface. There are extensive erosive surfaces of bright red color, moderately with serous hemorrhagic discharge, in places with open blisters and exfoliated epithelium, there are visible deep layers of the dermis



Right lower limb lateral surface. There are extensive erosive surfaces of bright red color, moderately with serous hemorrhagic discharge, and areas of exfoliated epithelium

Figure 2. Third day from the moment of admission (15.10.25).

and anterior chest, abdomen, and right lower limb. The skin in the area of the burn wounds consists of exfoliated, charred epidermis, extensive areas of pink de-epithelialization, foci of stasis, and the presence of serous blisters, in places, and ruptured blisters (Figure 1). The total burn area is 42% (IIIB - 25%). Sensitivity in the area of the burn wounds is decreased.

Electrocardiogram examination (12-lead ECG) with transcript (12.10.2025). Conclusion: sinus rhythm, heart rate of 85, vertical electrical axis. Echocardiography (13.10.2025): cardiac chamber sizes are within normal limits. Mild regurgitation on the mitral and tricuspid valves. Estimated pulmonary artery systolic pressure is 15 mmHg. Systolic and diastolic functions of the ventricles at rest are normal.

Computed tomography of the chest and mediastinum (12.10.2025): CT signs of bilateral lower lobe pneumonia. Effusion in the pleural cavities. Computed tomography of the neck (12.10.2025): CT signs of a fracture of the spinous process of the C7 vertebra. Computed tomography of the musculoskeletal system (1 anatomical zone) (12.10.2025): CT - no signs of traumatic or degenerative-dystrophic changes in the pelvic bones. Computed tomography of the abdominal organs and retroperitoneal space (12.10.2025): CT signs of perinephric effusion on the right? Artifacts. CT control.

Consultation with an otolaryngologist (14.10.2025): no acute ENT pathology at the time of examination. Consultation: Ophthalmologist (14.10.2025 15:21) Conclusion: Diagnosis: OU - Retinal angiopathy. Eyelid skin burn. Recommendations: 1. Treatment of the underlying disease. 2. Observation by an ophthalmologist at the place of residence. 3. Decreased volume of visual work at close range. 4. Slezol forte eye drops, 2 drops * 3 times a day - 30 days. 5. Blood pressure control. 6. Panthenol ointment, apply only around the eyes * 2 times a day, 10 days. Consultation with a rehabilitation specialist (13.10.2025). Prescribed: Individual kinesitherapy #24. Breathing exercises #24. Laser on foci #5. Consultation with a therapist (13.10.2025): Community-acquired bilateral lower lobe pneumonia. Respiratory failure 0-1. Saturation 97%. Consultation with a cardiologist (13.10.2025): at the time, there are no signs of heart damage. Consultation with an anesthesiologist-resuscitator (12.10.2025). Conclusion: given the absence of acute vital function disorders at the time of examination and treatment in a specialized department, additional laboratory and instrumental examinations are recommended to verify the

clinical diagnosis and implement recommendations. If the patient's condition worsens, or if the respiratory or cardiovascular system is impaired, a follow-up consultation with a resuscitation specialist is necessary.

Laboratory investigations on admission (12.10.2025):

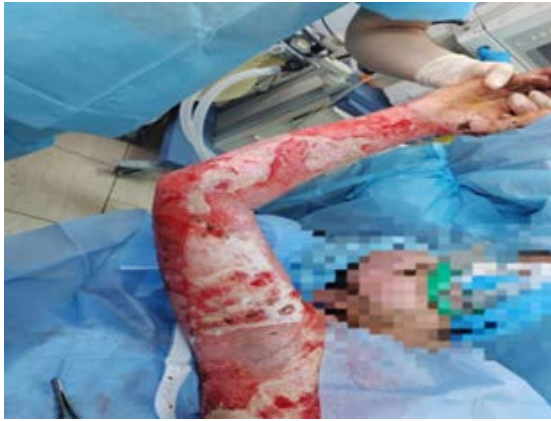Complete blood count: ESR 6 mm/h; leukocytes 13.70/L (normal range 4–9); erythrocytes (RBC) 4.36/L (normal range 4–5); hemoglobin (HGB) 140 g/L (normal range 130–160); hematocrit (HCT) 39.100% (normal range 32.5–49.5); platelets (PLT) 213.0/L (normal range 180–320); percentage (%) of lymphocytes (LYM%) 10.500% (normal range 25–40); absolute lymphocyte count (LYM#) 1.4/L (normal range 0.9–5); percentage (%) of neutrophils (NEUT%) 77.800% (normal range 35–70); absolute neutrophil count (NEUT#) 10.7/L (normal range 1.5–7.7); percentage (%) of mixed cells (monocytes, basophils, eosinophils) (MXD%) 11.700%; absolute mixed cell count (MXD#) 1.6/L (normal range 0.3–1.45).

Urinalysis: protein in urine neg g/L; ketone bodies in urine 4 mmol/L; leukocytes in urine 5 cells/μL (normal range 0–5); erythrocytes in urine 8 cells/μL (normal range 0–1); glucose in urine neg mmol/L; urine pH 6.5 (normal range 5–7); bilirubin in urine neg μmol/L; urine clarity – clear; relative density (specific gravity) of urine 1.010 (normal range 1.003–1.035); urobilinogen in urine 3.5 μmol/L; nitrites in urine neg cells/μL; ascorbic acid in urine neg mmol/L; urine color – yellow.

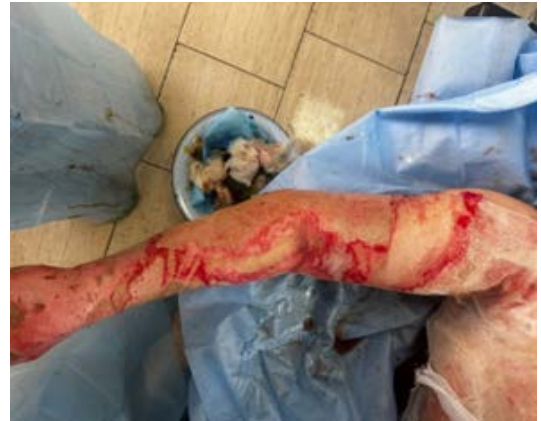Biochemical blood analysis: total serum protein 53.69 g/L (normal range 65–85); ALT 43.8 U/L (normal range 0–38); direct bilirubin in serum 6.60 μmol/L (normal range ≤5); total bilirubin in serum 19.89 μmol/L (normal range 0–20); AST 108.4 U/L (normal range 0–40); serum glucose 4.7 mmol/L (normal range 3.3–6.1); serum urea 2.78 mmol/L (normal range 1.8–8.3); blood creatinine 48.18 μmol/L (normal range 50–110); CRP 204.48 mg/L (normal range <5).

Coagulation profile: APTT (analyzer) 30.80 s; thrombin time (analyzer) 15.80 s (normal range 15–20); QFA (calculated) 5.852 g/L (normal range 2.2–3.97); INR 1.24 (normal range 0.8–1.36); prothrombin time (analyzer) 13.4 s (normal range 9–14); prothrombin index (analyzer) 70.8% (normal range 70–120).

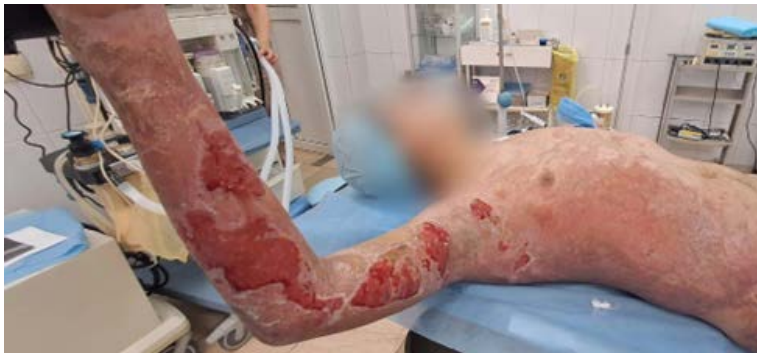Procalcitonin 0.26 ng/mL (normal range 0.1–0.5). Serum troponin (analyzer) 0.1 ng/mL (normal range <0.3).



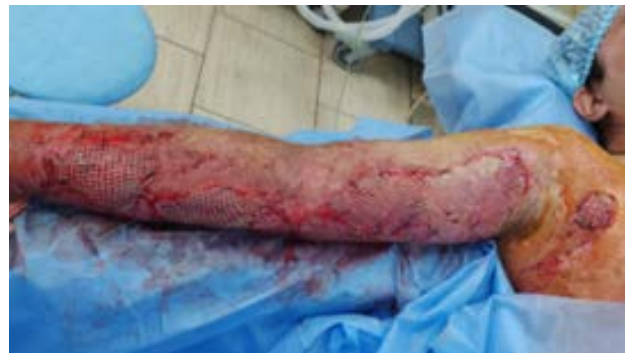A. Third day from the moment of admission: right upper limb (15.10.25). There are circular affected surfaces with isolated areas of necrosis, focal areas with deep de-epithelialized whitish-colored surfaces.



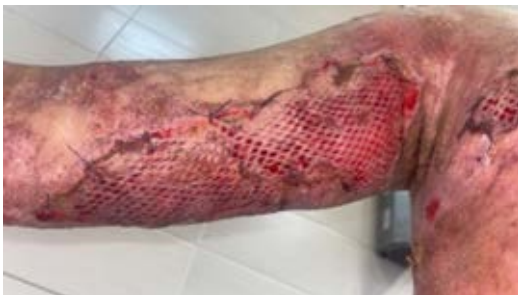B. Eighth day after admission (20.10.25). The right upper limb has burn surfaces of a circular nature, in the form of extensive areas of pale pink de-epithelialization, with areas of chiseled necrosis in the form of "dew drops". Foci of coagulation necrosis are noted



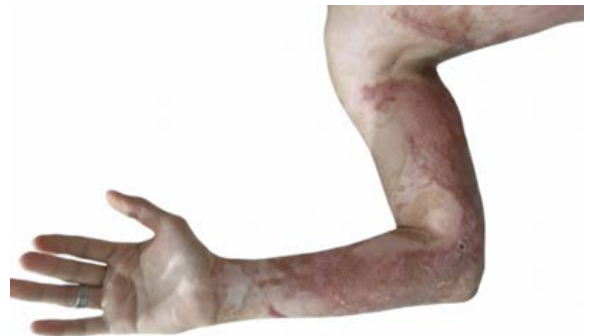C. 32 day from the moment of admission of the right upper limb: preparatory stage before autodermoplasty with a free split skin flap (13.11.25)



D. 32 day since admission, right upper limb. Condition after autodermoplasty with a free split-thickness skin flap using allogeneic human dermal fibroblast (13.11.25)



E. 36 day from the moment of admission of the right shoulder. 4th day after autodermoplasty with a free split-thickness skin flap using allogeneic human skin fibroblast



F. Condition after 2,5 months after treatment

Figure 3. Dynamics of changes in the local status of the right upper limb.

Diagnosis:

Electrical injury. Burn disease. Electrical injury. Electrical burn of grade 3AB of the face, neck, right upper limb, chest, anterior abdominal wall, right lower limb, covering 42% of the area (IIIB = 25%). Frank index 92 units. Severe burn shock as of 10.10.2025. Oculus dextra - Eyelid skin burn. Concomitant diagnosis: Community-acquired bilateral lower lobe pneumonia. RF 0-1. Saturation 97%. OU (Oculus Uterque: D and S) - Retinal angiopathy.

Treatment:

1. Pharmacological therapy: Sterofundin ISO 1000 mL; Enoxaparin 4,000 anti-Xa IU/0.4 mL (40 mg); Omegast 20 mg; Trofid 100 mg/2 mL; Diphenhydramine 1% (10 mg/mL);

Cefotaxime sodium 1 g; LevoKaz 5 mg/mL; Albuven 20%, 100 mL; Intrafen 800 mg/8 mL.

2. Surgical procedures: six staged necrectomies were performed: revision and debridement of burn wounds on 15.10.25; 20.10.25; 22.10.25; 24.10.25; 28.10.25; 31.10.25.

Surgery: Free split-thickness skin autografting with the use of allofibroblasts, dated 13.11.25. Allofibroblasts are produced by the Biotechnology Research Center of Astana and licensed in the Republic of Kazakhstan and are used in burn treatment (certificate No. 24952 dated November 22, 2024). The patient's consent for the use of allofibroblasts was obtained.

Performed under local anesthesia. Dressings over the burn wounds of the right upper extremity and chest were removed. After fourfold

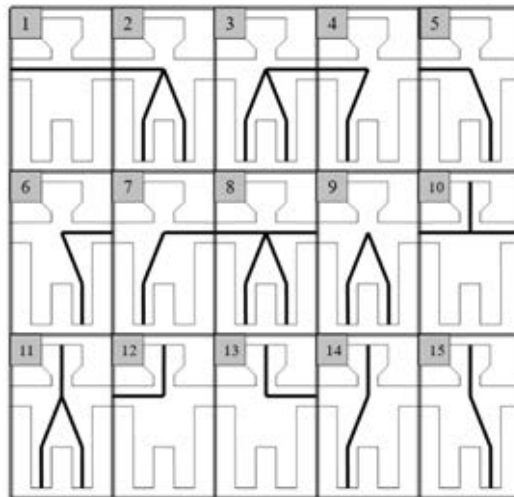


Figure 4. Characteristic paths of current in the human body.

treatment with povidone solution, the wound surface was irrigated with antiseptic solutions. On revision, the wounds of the right forearm and upper arm, as well as the right lateral chest wall, were covered with split-thickness autografts, which were subsequently fixed. Fibroblasts (spray) were applied to the wound surface. The total graft coverage area was 12%. Aseptic dressings were applied.

Discussion.

Electrical injuries can occur at home (faulty sockets, plugs, extension cords; household appliances; using electrical appliances near water; damaged wires, exposed contacts; attempting to repair electrical wiring without disconnecting the power); at work (with industrial equipment; high-voltage electrical installations; construction sites; safety violations; lack of personal protective equipment); and outdoors (downed power lines; transformer substations; street lighting; working in the rain or in high humidity). Cases of electrical injuries resulting from torture are also known [1-5].

A combination of factors, such as working under high voltage, near live devices, in moving trains, and at height, makes servicing overhead contact lines potentially hazardous for personnel. High voltage is known to have no visible signs. Moreover, wires that appear de-energized can retain an electrical charge due to induction from nearby lines, requiring employees to thoroughly understand and strictly adhere to safety regulations. Exposure to high-voltage electric current does not always require direct physical contact with the source and can be caused by indirect factors, such as step voltage or arcing. In this case, the patient's lack of alertness and awareness led to electrical injury.

The path of electric current through biological tissue is referred to as a "current loop." The greatest risk is posed by a "complete loop," characterized by current entering and exiting through the extremities (e.g., two arms, two legs), when the current inevitably crosses the heart, leading to rhythm disturbances, including asystole. It should be noted that the concept of discrete current paths in the body is somewhat arbitrary. Even with an identical "loop" configuration, current in the body is distributed across multiple parallel conducting media with variable resistance and branching, according to the principles outlined in Kirchhoff's laws. In this clinical example, we observe the "right arm - right leg" path (Figure 4, No. 4).

Electric shock causes abnormal electron flow through the body,

leading to serious consequences. This process disrupts the normal electrical homeostasis of cell membranes in nervous and muscle tissue, causing abnormal electrical impulses in the heart and central nervous system. Heating and vaporization of cell membranes as a result of the current leads to the formation of external and internal electrical burns. When passing through the brain, the current causes foci of abnormal depolarization of neuronal membranes, which is manifested by loss of consciousness (as experienced by this patient) and seizures.

The effects of electric current on the human body are multifaceted and include thermal, electrochemical, and biological effects [6]. When passing through tissue, electrical energy is converted into heat due to tissue resistance, according to Joule's law. Electrochemical processes lead to platelet and leukocyte aggregation, changes in the distribution of ions within and outside cells, and changes in protein structure. The patient's laboratory data indicate burn toxemia (neutrophilic leukocytosis, hematuria (likely related to catheterization), moderate ketonuria, elevated CRP, moderately elevated liver enzymes, slightly elevated direct bilirubin, hypoproteinemia, and elevated fibrinogen).

Electrochemical action leads to the accumulation of acidic products in the anode area and alkaline products in the cathode area. This results in tissue necrosis: coagulative necrosis under the anode and liquefactive necrosis under the cathode. A series of necrectomy procedures helps reduce the entry of toxic products into the blood and lymph, which reduces the degree of autointoxication, helps prevent purulent-septic complications, and prepares wounds for plastic surgery, which is what was performed in this patient.

Current local burn treatment practices include the use of both autologous and heterogeneous biological materials, such as alloderm, transcyte, Integra, ApliGraf, human amnion, and others [7-9]. Evidence confirms their ability to accelerate healing, protect against infection, and reduce pain during dressing changes [7,13]. However, the high cost of these commercial wound dressings significantly limits their widespread use; several are also in preclinical testing [8,9,12].

However, autodermografting remains the gold standard for treating deep burns [10,11], which involves using the patient's own skin to close the burn wound, minimizing the risk of immune rejection, ensuring good graft survival, and providing functional closure of the defect.

The pathogenetic mechanism of action of the proposed method

is as follows: 1. Synthesis by fibroblasts of carbohydrate-protein complexes of the basic substance (glycosaminoglycans, hyaluronic acid, nidogen, laminin, tinascin, chondroitin-4-sulfate, proteoglycans); 2. Production of growth factors: basic fibroblast growth factor (bFGF), transforming growth factor (TGF- α , TGF- β), growth factor (TGF β 1), epidermal growth factor (EGF), keratinocyte growth factor (KGF), transforming growth factor (a-NGF), endothelial growth factor blood vessels (VEGF); 3. Formation of collagen, elastic and reticular fibers. In combination with fibrous components, fibroblasts determine the spatial structure (architectonics) of connective tissue; 4. Stimulation of the proliferation of its own epithelium, aimed at restoring both the epi-dermal and dermal components of the skin. The transplanted fibroblasts stimulate keratinocyte adhesion and proliferation of these cells; 5. Similar to mononuclear immunocytes, they are capable of producing pro-inflammatory cytokines such as IL 1, TNF, IL-8, and colony-stimulating factors [14].

The use of allogeneic fibroblasts in the treatment of burn wounds demonstrates significant regenerative potential, as confirmed by both experimental and clinical studies [15]. The key mechanism of their action is paracrine activity, including the secretion of growth factors (VEGF, FGF, TGF- β), which stimulate angiogenesis, keratinocyte proliferation, and the formation of granulation tissue. The use of fibroblast-containing dermal equivalents has been shown to accelerate epithelialization and improve the quality of skin regeneration [16]. Furthermore, allofibroblasts participate in extracellular matrix remodeling through the synthesis of collagen and fibronectin, and also have an immunomodulatory effect, reducing the severity of the inflammatory response [17]. A significant advantage of this approach is improved skin graft engraftment and a reduced risk of scarring, which is particularly relevant for deep burns [18]. Thus, the accumulated data demonstrate the high efficacy of allogeneic fibroblasts as a component of cellular technologies in burn treatment. However, further research is needed to standardize protocols for their use and evaluate long-term outcomes.

Conclusion.

Comprehensive transfusion, anti-shock, antibacterial, and analgesic therapy stabilized hemodynamics, corrected hypovolemia, reduced pain, prevented the development of infectious complications, and paved the way for subsequent stages of surgical treatment: serial necrectomy with autografting using a free split-thickness skin graft and allogeneic human dermal fibroblast. Despite the severity of the electrical injury, thanks to a multidisciplinary approach and comprehensive treatment, the patient was discharged in satisfactory condition for outpatient treatment.

Author Contributions.

Conceptualization – BT, RM; methodology – SS, formal analysis – BT, SS; writing – original draft preparation – ZB, RM, EJ; writing – review and editing – KA; visualization – ZB.

All authors have read and agreed to the published version of the manuscript.

REFERENCES

1. Ahmed J, Stenkula C, Omar S. Patient outcomes after electrical injury - a retrospective study. *Scand J Trauma Resusc Emerg Med.* 2021;29:114.
2. Zemaitis MR, Guirguis M, Cindass R. Electrical Injuries.

In: StatPearls [Internet]. Treasure Island (FL): StatPearls Publishing; 2025.

3. Shih J, Shahrokh S, Jeschke MG. Review of Adult Electrical Burn Injury Outcomes Worldwide: An Analysis of Low-Voltage vs High-Voltage Electrical Injury. *Journal of burn care & research: official publication of the American Burn Association.* 2017;38:e293-e298.
4. Daskal Y, Beicker A, Dudkiewicz M, et al. High voltage electric injury: mechanism of injury, clinical features and initial evaluation. *Harefuah.* 2019;158:65-69.
5. Alqassab S, Mathieu L. Torture-induced hand electrical injury: A case report. *J Forensic Leg Med.* 2021;77:102085.
6. Mansueti G, Di Napoli M, Mascolo P, et al. Electrocutation stigmas in organ damage: the pathological marks. *Diagnostics.* 2021;11:682.
7. Tuleubayev B, Ogay V, Anapiya B, et al. Therapeutic Treatment of 2A Grade Burns with Decellularized Bovine Peritoneum as a Xenograft: Multicenter Randomized Clinical Trial. *Medicina.* 2022;58:819.
8. Luze H, Holzer J, Tiffner K, et al. Bacterial Nanocellulose as Cooling Agent. *Journal of Burn Care & Research.* 2020;41:152-153.
9. Rashova M, Amirkhanova Z, Akhmetova S, et al. Assessment of Antibacterial and Antifungal Activity of a Biocomposite Based on Nanocellulose in Vitro. *J CLIN MED KAZ.* 2025;22:53-7.
10. Jorgensen A, Mahajan N, Atala A, et al. Advances in Skin Tissue Engineering and Regenerative Medicine. *Journal of Burn Care & Research.* 2023;44:33-41.
11. Varkey M, Visscher DO, Zuijlen P, et al. Skin bioprinting: the future of burn wound reconstruction? *Burns & Trauma.* 2019;7:41038.
12. Abatov N.T, Badyrov R.M, Urazbayev N.K, et al. Histomorphometric evaluation of the tissue response to xenogeneic extracellular peritoneal matrix and synthetic UltraPro mesh under conditions of *Pseudomonas Aeruginosa* infection. *Bulletin of Experimental Biology and Medicine.* 2025;180:647-653.
13. Akhmediya R.E, Ikhambayeva A.N, Akhmadyar N.S, et al. Non-steroid anti-inflammatory drugs: recommendations and precautions for safe use in a multidisciplinary surgical department. *Medicine and ecology.* 2024;3:105-112.
14. Van Der Leeden B, Korkmaz HI, Roffel s, et al. Fibroblast Dynamics Following Partial and Deep Burn Injury in a Reconstructed Human Skin Model. *Tissue Engineering and Regenerative Medicine.* 2025;1-14.
15. MacNeil S. Progress and opportunities for tissue-engineered skin. *Nature.* 2007;445:874-80.
16. Rahnama M, Ghasemzadeh N, Ebrahimi Y, et al. A comprehensive evaluation of dermal fibroblast therapy in clinical trials for treating skin disorders and cosmetic applications: a scoping review. *Stem Cell Res Ther.* 2024;15:318.
17. Falanga VJ. Tissue engineering in wound repair. *Adv Skin Wound Care.* 2000;13:15-9.
18. Boyce ST, Kagan RJ, Yakuboff KP, et al. Cultured skin substitutes reduce donor skin harvesting for closure of excised, full-thickness burns. *Ann Surg.* 2002;235:269-79.