

GEORGIAN MEDICAL NEWS

ISSN 1512-0112

NO 9 (354) Сентябрь 2024

ТБИЛИСИ - NEW YORK



ЕЖЕМЕСЯЧНЫЙ НАУЧНЫЙ ЖУРНАЛ

Медицинские новости Грузии
საქართველოს სამედიცინო სიახლენი

GEORGIAN MEDICAL NEWS

Monthly Georgia-US joint scientific journal published both in electronic and paper formats of the Agency of Medical Information of the Georgian Association of Business Press.
Published since 1994. Distributed in NIS, EU and USA.

GMN: Georgian Medical News is peer-reviewed, published monthly journal committed to promoting the science and art of medicine and the betterment of public health, published by the GMN Editorial Board since 1994. GMN carries original scientific articles on medicine, biology and pharmacy, which are of experimental, theoretical and practical character; publishes original research, reviews, commentaries, editorials, essays, medical news, and correspondence in English and Russian.

GMN is indexed in MEDLINE, SCOPUS, PubMed and VINITI Russian Academy of Sciences. The full text content is available through EBSCO databases.

GMN: Медицинские новости Грузии - ежемесячный рецензируемый научный журнал, издаётся Редакционной коллегией с 1994 года на русском и английском языках в целях поддержки медицинской науки и улучшения здравоохранения. В журнале публикуются оригинальные научные статьи в области медицины, биологии и фармации, статьи обзорного характера, научные сообщения, новости медицины и здравоохранения. Журнал индексируется в MEDLINE, отражён в базе данных SCOPUS, PubMed и ВИНТИ РАН. Полнотекстовые статьи журнала доступны через БД EBSCO.

GMN: Georgian Medical News – საქართველოს სამედიცინო სიახლენი – არის ყოველთვიური სამეცნიერო სამედიცინო რეცენზირებადი ჟურნალი, გამოიცემა 1994 წლიდან, წარმოადგენს სარედაქციო კოლეგიისა და აშშ-ის მეცნიერების, განათლების, ინდუსტრიის, ხელოვნებისა და ბუნებისმეტყველების საერთაშორისო აკადემიის ერთობლივ გამოცემას. GMN-ში რუსულ და ინგლისურ ენებზე ქვეყნდება ექსპერიმენტული, თეორიული და პრაქტიკული ხასიათის ორიგინალური სამეცნიერო სტატიები მედიცინის, ბიოლოგიისა და ფარმაციის სფეროში, მიმოხილვითი ხასიათის სტატიები.

ჟურნალი ინდექსირებულია MEDLINE-ის საერთაშორისო სისტემაში, ასახულია SCOPUS-ის, PubMed-ის და ВИНТИ РАН-ის მონაცემთა ბაზებში. სტატიების სრული ტექსტი ხელმისაწვდომია EBSCO-ს მონაცემთა ბაზებში.

WEBSITE

www.geomednews.com

К СВЕДЕНИЮ АВТОРОВ!

При направлении статьи в редакцию необходимо соблюдать следующие правила:

1. Статья должна быть представлена в двух экземплярах, на русском или английском языках, напечатанная через **полтора интервала на одной стороне стандартного листа с шириной левого поля в три сантиметра**. Используемый компьютерный шрифт для текста на русском и английском языках - **Times New Roman (Кириллица)**, для текста на грузинском языке следует использовать **AcadNusx**. Размер шрифта - **12**. К рукописи, напечатанной на компьютере, должен быть приложен CD со статьей.

2. Размер статьи должен быть не менее десяти и не более двадцати страниц машинописи, включая указатель литературы и резюме на английском, русском и грузинском языках.

3. В статье должны быть освещены актуальность данного материала, методы и результаты исследования и их обсуждение.

При представлении в печать научных экспериментальных работ авторы должны указывать вид и количество экспериментальных животных, применявшиеся методы обезболивания и усыпления (в ходе острых опытов).

4. К статье должны быть приложены краткое (на полстраницы) резюме на английском, русском и грузинском языках (включающее следующие разделы: цель исследования, материал и методы, результаты и заключение) и список ключевых слов (key words).

5. Таблицы необходимо представлять в печатной форме. Фотокопии не принимаются. **Все цифровые, итоговые и процентные данные в таблицах должны соответствовать таковым в тексте статьи.** Таблицы и графики должны быть озаглавлены.

6. Фотографии должны быть контрастными, фотокопии с рентгенограмм - в позитивном изображении. Рисунки, чертежи и диаграммы следует озаглавить, пронумеровать и вставить в соответствующее место текста **в tiff формате**.

В подписях к микрофотографиям следует указывать степень увеличения через окуляр или объектив и метод окраски или импрегнации срезов.

7. Фамилии отечественных авторов приводятся в оригинальной транскрипции.

8. При оформлении и направлении статей в журнал МНГ просим авторов соблюдать правила, изложенные в «Единых требованиях к рукописям, представляемым в биомедицинские журналы», принятых Международным комитетом редакторов медицинских журналов - <http://www.spinesurgery.ru/files/publish.pdf> и http://www.nlm.nih.gov/bsd/uniform_requirements.html. В конце каждой оригинальной статьи приводится библиографический список. В список литературы включаются все материалы, на которые имеются ссылки в тексте. Список составляется в алфавитном порядке и нумеруется. Литературный источник приводится на языке оригинала. В списке литературы сначала приводятся работы, написанные знаками грузинского алфавита, затем кириллицей и латиницей. Ссылки на цитируемые работы в тексте статьи даются в квадратных скобках в виде номера, соответствующего номеру данной работы в списке литературы. Большинство цитированных источников должны быть за последние 5-7 лет.

9. Для получения права на публикацию статья должна иметь от руководителя работы или учреждения визу и сопроводительное отношение, написанные или напечатанные на бланке и заверенные подписью и печатью.

10. В конце статьи должны быть подписи всех авторов, полностью приведены их фамилии, имена и отчества, указаны служебный и домашний номера телефонов и адреса или иные координаты. Количество авторов (соавторов) не должно превышать пяти человек.

11. Редакция оставляет за собой право сокращать и исправлять статьи. Корректур авторам не высылаются, вся работа и сверка проводится по авторскому оригиналу.

12. Недопустимо направление в редакцию работ, представленных к печати в иных издательствах или опубликованных в других изданиях.

При нарушении указанных правил статьи не рассматриваются.

REQUIREMENTS

Please note, materials submitted to the Editorial Office Staff are supposed to meet the following requirements:

1. Articles must be provided with a double copy, in English or Russian languages and typed or computer-printed on a single side of standard typing paper, with the left margin of 3 centimeters width, and 1.5 spacing between the lines, typeface - **Times New Roman (Cyrillic)**, print size - 12 (referring to Georgian and Russian materials). With computer-printed texts please enclose a CD carrying the same file titled with Latin symbols.

2. Size of the article, including index and resume in English, Russian and Georgian languages must be at least 10 pages and not exceed the limit of 20 pages of typed or computer-printed text.

3. Submitted material must include a coverage of a topical subject, research methods, results, and review.

Authors of the scientific-research works must indicate the number of experimental biological species drawn in, list the employed methods of anesthetization and soporific means used during acute tests.

4. Articles must have a short (half page) abstract in English, Russian and Georgian (including the following sections: aim of study, material and methods, results and conclusions) and a list of key words.

5. Tables must be presented in an original typed or computer-printed form, instead of a photocopied version. **Numbers, totals, percentile data on the tables must coincide with those in the texts of the articles.** Tables and graphs must be headed.

6. Photographs are required to be contrasted and must be submitted with doubles. Please number each photograph with a pencil on its back, indicate author's name, title of the article (short version), and mark out its top and bottom parts. Drawings must be accurate, drafts and diagrams drawn in Indian ink (or black ink). Photocopies of the X-ray photographs must be presented in a positive image in **tiff format**.

Accurately numbered subtitles for each illustration must be listed on a separate sheet of paper. In the subtitles for the microphotographs please indicate the ocular and objective lens magnification power, method of coloring or impregnation of the microscopic sections (preparations).

7. Please indicate last names, first and middle initials of the native authors, present names and initials of the foreign authors in the transcription of the original language, enclose in parenthesis corresponding number under which the author is listed in the reference materials.

8. Please follow guidance offered to authors by The International Committee of Medical Journal Editors guidance in its Uniform Requirements for Manuscripts Submitted to Biomedical Journals publication available online at: http://www.nlm.nih.gov/bsd/uniform_requirements.html
http://www.icmje.org/urm_full.pdf

In GMN style for each work cited in the text, a bibliographic reference is given, and this is located at the end of the article under the title "References". All references cited in the text must be listed. The list of references should be arranged alphabetically and then numbered. References are numbered in the text [numbers in square brackets] and in the reference list and numbers are repeated throughout the text as needed. The bibliographic description is given in the language of publication (citations in Georgian script are followed by Cyrillic and Latin).

9. To obtain the rights of publication articles must be accompanied by a visa from the project instructor or the establishment, where the work has been performed, and a reference letter, both written or typed on a special signed form, certified by a stamp or a seal.

10. Articles must be signed by all of the authors at the end, and they must be provided with a list of full names, office and home phone numbers and addresses or other non-office locations where the authors could be reached. The number of the authors (co-authors) must not exceed the limit of 5 people.

11. Editorial Staff reserves the rights to cut down in size and correct the articles. Proof-sheets are not sent out to the authors. The entire editorial and collation work is performed according to the author's original text.

12. Sending in the works that have already been assigned to the press by other Editorial Staffs or have been printed by other publishers is not permissible.

**Articles that Fail to Meet the Aforementioned
Requirements are not Assigned to be Reviewed.**

ავტორთა საყურადღებო!

რედაქციაში სტატიის წარმოდგენისას საჭიროა დავიცვათ შემდეგი წესები:

1. სტატია უნდა წარმოადგინოთ 2 ცალად, რუსულ ან ინგლისურ ენებზე, დაბეჭდილი სტანდარტული ფურცლის 1 გვერდზე, 3 სმ სიგანის მარცხენა ველისა და სტრიქონებს შორის 1,5 ინტერვალის დაცვით. გამოყენებული კომპიუტერული შრიფტი რუსულ და ინგლისურენოვან ტექსტებში - **Times New Roman (Кириллица)**, ხოლო ქართულენოვან ტექსტში საჭიროა გამოვიყენოთ **AcadNusx**. შრიფტის ზომა – 12. სტატიას თან უნდა ახლდეს CD სტატიით.

2. სტატიის მოცულობა არ უნდა შეადგენდეს 10 გვერდზე ნაკლებს და 20 გვერდზე მეტს ლიტერატურის სიის და რეზიუმეების (ინგლისურ, რუსულ და ქართულ ენებზე) ჩათვლით.

3. სტატიაში საჭიროა გაშუქდეს: საკითხის აქტუალობა; კვლევის მიზანი; საკვლევი მასალა და გამოყენებული მეთოდები; მიღებული შედეგები და მათი განსჯა. ექსპერიმენტული ხასიათის სტატიების წარმოდგენისას ავტორებმა უნდა მიუთითონ საექსპერიმენტო ცხოველების სახეობა და რაოდენობა; გაუტკივარებისა და დაძინების მეთოდები (მწვავე ცდების პირობებში).

4. სტატიას თან უნდა ახლდეს რეზიუმე ინგლისურ, რუსულ და ქართულ ენებზე არანაკლებ ნახევარი გვერდის მოცულობისა (სათაურის, ავტორების, დაწესებულების მითითებით და უნდა შეიცავდეს შემდეგ განყოფილებებს: მიზანი, მასალა და მეთოდები, შედეგები და დასკვნები; ტექსტუალური ნაწილი არ უნდა იყოს 15 სტრიქონზე ნაკლები) და საკვანძო სიტყვების ჩამონათვალი (key words).

5. ცხრილები საჭიროა წარმოადგინოთ ნაბეჭდი სახით. ყველა ციფრული, შემავჯამებელი და პროცენტული მონაცემები უნდა შეესაბამებოდეს ტექსტში მოყვანილს.

6. ფოტოსურათები უნდა იყოს კონტრასტული; სურათები, ნახაზები, დიაგრამები - დასათაურებული, დანომრილი და სათანადო ადგილას ჩასმული. რენტგენოგრაფიის ფოტოსურათები წარმოადგინეთ პოზიტიური გამოსახულებით **tiff** ფორმატში. მიკროფოტოსურათების წარწერებში საჭიროა მიუთითოთ ოკულარის ან ობიექტივის საშუალებით გადიდების ხარისხი, ანათალების შედეგების ან იმპრეგნაციის მეთოდი და აღნიშნოთ სურათის ზედა და ქვედა ნაწილები.

7. სამამულო ავტორების გვარები სტატიაში აღინიშნება ინიციალების თანდართვით, უცხოურისა – უცხოური ტრანსკრიპციით.

8. სტატიას თან უნდა ახლდეს ავტორის მიერ გამოყენებული სამამულო და უცხოური შრომების ბიბლიოგრაფიული სია (ბოლო 5-8 წლის სიღრმით). ანბანური წყობით წარმოდგენილ ბიბლიოგრაფიულ სიაში მიუთითეთ ჯერ სამამულო, შემდეგ უცხოელი ავტორები (გვარი, ინიციალები, სტატიის სათაური, ჟურნალის დასახელება, გამოცემის ადგილი, წელი, ჟურნალის №, პირველი და ბოლო გვერდები). მონოგრაფიის შემთხვევაში მიუთითეთ გამოცემის წელი, ადგილი და გვერდების საერთო რაოდენობა. ტექსტში კვადრატულ ფხიხლებში უნდა მიუთითოთ ავტორის შესაბამისი N ლიტერატურის სიის მიხედვით. მიზანშეწონილია, რომ ციტირებული წყაროების უმეტესი ნაწილი იყოს 5-6 წლის სიღრმის.

9. სტატიას თან უნდა ახლდეს: ა) დაწესებულების ან სამეცნიერო ხელმძღვანელის წარდგინება, დამოწმებული ხელმოწერითა და ბეჭდით; ბ) დარგის სპეციალისტის დამოწმებული რეცენზია, რომელშიც მითითებული იქნება საკითხის აქტუალობა, მასალის საკმაობა, მეთოდის სანდოობა, შედეგების სამეცნიერო-პრაქტიკული მნიშვნელობა.

10. სტატიის ბოლოს საჭიროა ყველა ავტორის ხელმოწერა, რომელთა რაოდენობა არ უნდა აღემატებოდეს 5-ს.

11. რედაქცია იტოვებს უფლებას შეასწოროს სტატია. ტექსტზე მუშაობა და შეჯერება ხდება საავტორო ორიგინალის მიხედვით.

12. დაუშვებელია რედაქციაში ისეთი სტატიის წარდგენა, რომელიც დასაბეჭდად წარდგენილი იყო სხვა რედაქციაში ან გამოქვეყნებული იყო სხვა გამოცემებში.

აღნიშნული წესების დარღვევის შემთხვევაში სტატიები არ განიხილება.

Teona Avaliani, Nino Kiria, Nino Bablishvili, Giorgi Pichkhia, Lali Sharvadze, Nana Kiria. USAGE OF SILVER NANOPARTICLES TO RESTORE MOXIFLOXACIN EFFICACY FOR FLUOROQUINOLONE-RESISTANT M.TUBERCULOSIS CULTURES.....	6-12
Kien Tran, Hung Kieu Dinh, Ha Duong Dai, Tan Hoang Minh, Van Hoang thi Hong, Trang Nguyen Thi Huyen, Mai Bui Thi. EFFECTIVENESS IN INDIRECT DECOMPRESSION USING MINIMALLY INVASIVE SURGERY – TRANSFORAMINAL LUMBAR INTERBODY FUSION IN SINGLE-LEVEL LUMBOSACRAL SPONDYLOLISTHESIS.....	13-18
Yuriy Prudnikov, Olha Yuryk, Mykhailo Sosnov, Anatoliy Stashkevych, Stepan Martsyniak. USE OF ARTIFICIAL INTELLIGENCE IN THE DIAGNOSIS AND TREATMENT OF ORTHOPEDIC DISEASES: LITERATURE REVIEW.....	19-31
Blerita Latifi-Xhemajli. EFFECTIVENESS OF XYLITOL TOOTHPASTE IN CARIES PREVENTION: A REVIEW ARTICLE.....	32-35
Bukia Nato, Machavariani Lamara, Butskhrikidze Marina, Svanidze Militsa, Siradze Mariam. ELECTROMAGNETIC STIMULATION REGULATES BLOOD CORTICOSTERONE LEVELS IN IMMOBILIZED RATS: GENDER DIFFERENCES.....	36-41
Arnab Sain, Urvashi Ghosh, Jack Song Chia, Minaal Ahmed Malik, Nauman Manzoor, Michele Halasa, Fahad Hussain, Hamdoon Asim, Kanishka Wattage, Hoosai Manyar, Ahmed Elkilany, Anushka Jindal, Justin Wilson, Nadine Khayyat, Hannah Burton, Wilam Ivanga Alfred, Vivek Deshmukh, Zain Sohail, Nirav Shah. RECENT TRENDS IN THE USE OF CELL SALVAGER FOR ORTHOPAEDIC TRAUMA AND ELECTIVE SURGERIES-A NARRATIVE REVIEW.....	42-44
Yu.V. Boldyreva, D.G. Gubin, I.A. Lebedev, E.V. Zakharchuk, I.V. Pashkina. ANALYSIS OF BLOOD PARAMETERS IN TYUMEN RESIDENTS WITH COVID-19 IN CATAMNESIS AND/OR VACCINATED AGAINST A NEW CORONAVIRUS INFECTION.....	45-48
Abuova Zh.Zh, Buleshov M.A, Zhaksybergenov A.M, Assilbekova G, Mailykaraeva A.A. THE STUDY OUTCOMES OF THE NEGATIVE IMPACT OF HEXACHLOROCYCLOHEXANE ON VEGETOVASCULAR REGULATION OF NEWBORNS' CARDIAC RHYTHM.....	49-56
Rostomov Faizo E, Sashkova Angelina E, Kruglikov Nikita S, Postnova Elina V, Nasirov Said F.O, Barinova Olga V, Repina Anastasiia F, Kodzokova Farida A, Abdulmanatov Magomedemin K, Dzhamalova Asiat M. THE ROLE OF PSYCHOLOGICAL STRESS IN THE DEVELOPMENT OF ESSENTIAL ARTERIAL HYPERTENSION IN ELDERLY PEOPLE.....	57-59
Hamdoon Asim, Arnab Sain, Nauman Manzoor, Mariam Nausherwan, Minaal Ahmed Malik, Fahad Hussain, Mohammad Bilal, Haris Khan, Amir Varasteh, Anushka Jindal, Mohammad Zain Sohail, Nadine Khayyat, Kanishka Wattage, Michele Halasa, Jack Song Chia, Justin Wilson. THE PREVALENCE OF SARCOPENIA AND ITS EFFECTS ON OUTCOMES IN POLYTRAUMA.....	60-65
Sergo Kobalava, Mikheil Tsverava, Eteri Tsetskhladze. CHRONIC HEART FAILURE WITH PRESERVED LEFT VENTRICLE EJECTION FRACTION (HFPEF) AND RIGHT VENTRICLE INVOLVEMENT IN PATIENTS WITH NORMAL SINUS RHYTHM AND ATRIAL FIBRILLATION; A SMALL OBSERVATIONAL STUDY: RELEVANCE OF THE PROBLEM, DIAGNOSTIC APPROACH, ECHOCARDIOGRAPHIC EVALUATION OF RIGHT VENTRICLE.....	66-74
Sergey V. Osminin, Fedor P. Vetshev, Ildar R. Bilyalov, Marina O. Astaeva, Yevgeniya V. Yeventyeva. PERIOPERATIVE FLOT CHEMOTHERAPY FOR GASTRIC CANCER: A RETROSPECTIVE SINGLE-CENTER COHORT TRIAL....	75-81
Iskandar M. Alardi, Abbas AA. Kadhim, Ali SM. Aljanabi. PERONEUS LONGUS (PL) AUTOGRAFT IN ANTERIOR CRUCIATE LIGAMENT RECONSTRUCTION AS ALTERNATIVE GRAFT OPTION.....	82-84
Chayakova Akerke, Aiman Musina, Aldanysh Akbolat. TRENDS IN EMERGENCY MEDICAL CALLS BEFORE AND AFTER COVID-19 IN KAZAKHSTAN.....	85-91
Lipatov K.V, Komarova E.A, Solov'eva E.I, Kazantsev A.D, Gorbacheva I.V, Sotnikov D.N, Voinov M.A, Avdienko E.V, Shevchuk A.S, Sarkisyan I.P. MORE ON DEEP HEMATOMAS IN PATIENTS WITH COVID-19: CASE SERIES.....	92-99
Ling-Ling Zhou, Chu-Ying Gao, Jing-Jin Yang, Yong Liang, Lian-Ping He. CURRENT SITUATION AND COUNTERMEASURES OF TALENT TEAM CONSTRUCTION IN THE FIELD OF GRASSROOTS PUBLIC HEALTH.....	100-103
Arnab Sain, Urvashi Ghosh, Michele Halasa, Minaal Ahmed Malik, Nauman Manzoor, Jack Song Chia, Hamdoon Asim, Nadine Khayyat, Kanishka Wattage, Hoosai Manyar, Ahmed Elkilany, Anushka Jindal, Justin Wilson, Fahad Hussain, Hannah Burton, Wilam Ivanga Alfred, Vivek Deshmukh, Zain Sohail, Nirav Shah. USE OF TANTALUM CUP IN TOTAL HIP ARTHROPLASTY-A NARRATIVE REVIEW.....	104-106

Oula E. Hadi, Eman Hashim Yousif. HISTOLOGICAL EXAMINATION OF THE EFFECT OF URANIUM ON UDDER CELLS.....	107-115
Tchernev G, Pidakev I, Lozev I, Warbev M, Ivanova V, Broshtilova V. DERMATOLOGIC SURGERY: ROTATION ADVANCEMENT FLAP AS FIRST LINE TREATMENT FOR HIGH-RISK SQUAMOUS CELL CARCINOMAS OF THE PERIOCLAR/PERIORBITAL ZONE- PRESENTATION AND DISCUSSION ABOUT 2 NEW CASES.....	116-121
Osminina M.K, Podchernyaeva N.S, Khachatryan L.G, Shpitonkova O.V, Velikoretskaya M.D, Chebysheva S. N, Polyanskaya A.V, Gugueva E. A. STROKE AS A LIFE-THREATENING COMPLICATION IN CHILDREN WITH LINEAR SCLERODERMA OF FACE.....	122-128
D. Elgandashvili, Al. Kalantarov, T. Gugeshashvili. MAYER–ROKITANSKY–KUSTER–HAUSER SYNDROME. LAPAROSCOPIC SIGMOID VAGINOPLASTY FOR THE TREATMENT OF VAGINAL AGENESIS - SINGLE CENTER EXPERIENCE IN GEORGIA-CASE REPORT.....	129-138
Gocha Chankseliani, Merab Kiladze, Avtandil Girdaladze, Omar Gibradze. SUCCESSFUL EMERGENCY ARTERIAL EMBOLIZATION FOR MASSIVE GASTRODUODENAL BLEEDING IN HIGH-RISK PATIENT: CASE REPORT.....	139-142
Dildar MM. Mostafa, Mohammed T. Rasool. PREVALENCE OF OSTEOPOROSIS IN PATIENTS WITH RHEUMATOID ARTHRITIS IN IRAQI KURDISTAN /DUHOK GOVERNORATE.....	143-148
Arustamyan Makich, Guseynova Susanna V, Tyulekbayeva Diana, Tkhakokhova Liana A, Krivosheeva Yana V, Vasilev Semen A, Abbasova Zeinab I, Ponomareko Nadezhda O, Ismailova Sabina Z, Zakaev Israpil I. COMPARATIVE ANALYSIS OF HEPATOPROTECTORS IN WISTAR RATS WITH EXPERIMENTALLY INDUCED METABOLICALLY ASSOCIATED FATTY LIVER DISEASE.....	149-150
Jin Wu, Lan-Xi Wu, Kun Yan, Jun-You Li, Tao-Xiang Niu. ALOPECIA AREATA PROFILING SHOWS LNCRNAs REGULATE THE SUPPRESSED EXPRESSION OF KERATIN.....	151-159
Chkhaidze B, Loria L. EVALUATION OF THE FUNCTIONAL CHARACTERISTICS OF THE UNIVERSAL HEALTHCARE PROGRAM BY MEDICAL PERSONNEL IN TBILISI.....	160-164
Osminina M.K, Podchernyaeva N.S, Khachatryan L.G, Shpitonkova O.V, Polyanskaya A.V, Chebysheva S.N, Velikoretskaya M.D. JOINT LESIONS – COMMON EXTRACUTANEOUS MANIFESTATION IN JUVENILE LOCALIZED SCLERODERMA.....	165-172
Haval J. Ali, Zeki A. Mohamed, Dana A. Abdullah. HEALTH-RELATED QUALITY OF LIFE IN CHRONIC MYELOID LEUKAEMIA PATIENTS RECEIVING LONG-TERM THERAPY WITH DIFFERENT TYROSINE KINASE INHIBITORS IN KURDISTAN REGION.....	173-180
Arnab Sain, Ahmed Elkilany, Minaal Ahmed Malik, Nauman Manzoor, Nadine Khayyat, Hoosai Manyar, Michele Halasa, Jack Song Chia, Fahad Hussain, Hamdoon Asim, Kanishka Wattage, Anushka Jindal, Justin Wilson, Hannah Burton, Wilam Ivanga Alfred, Vivek Deshmukh, Zain Sohail. THE USE OF ANKLE BLOCK FOR ACUTE ANKLE FRACTURE REDUCTION: A REVIEW OF CURRENT LITERATURE.....	181-183
Megrelishvili Tamar, Mikadze Ia, Kipiani Nino, Mamuchishvili Nana, Bochorishvili Tea, Imnadze Tamar, Pachkoria Elene, Ratiani Levan. CLINICAL MANIFESTATION AND EPIDEMIOLOGICAL PECULIARITIES OF LEPTOSPIROSIS AT THE MODERN STAGE IN GEORGIA.....	184-187
Raikhan Bekmagambetova, Zulfiya Kachiyeva, Zhanat Ispayeva, Ildar Fakhradiyev, Maia Gotua, Roza Kenzhebekova, Aiganym Tolegenkyzy, Kristina Kovaleva, Gulbarash Turlugulova, Aigerim Zhakiyeva, Nazgul Janabayeva, Kunsulu Rysmakhanova. GENETIC ASSOCIATIONS WITH ASTHMA IN THE KAZAKH POPULATION: A CASE-CONTROL STUDY FOCUSING ON ACTN3 AND TSBP1 POLYMORPHISMS.....	188-194
Farah Saleh Abdul-Reda, Mohammed AH Jabarah AL-Zobaidy. EFFECTIVENESS AND TOLERABILITY OF APREMILAST IN TREATMENT OF A SAMPLE OF PATIENTS WITH PSORIASIS...	195-198
Emma Gevorkyan, Ruzanna Shushanyan, Karine Hovhannisyan, Marietta Karapetyan, Anna Karapetyan. ASSESSMENT OF CHANGES IN HEART RATE VARIABILITY INDICES OF STUDENTS AFTER COVID-19 LOCKDOWN: A COHORT STUDY.....	199-204
Alharbi Badr, Alwashmi Emad, Aloraini Abdullah Saleh, Almanian Ali Ibrahim, Alsuhailbani Ali Abdullah, Aloraini Husam Yosuf, Alhwiriny Abdullah Nasser, Altwairgi Adil Khalaf. PERCEPTION OF UROLOGY SPECIALTY AND FACTORS INFLUENCE ITS CONSIDERATION AS A CAREER CHOICE AMONG MEDICALSTUDENTS.....	205-212
Tamuna Dundua, Vladimer Margvelashvili, Manana Kalandadze, Sopio Dalalishvili. THE ORAL HEALTH STATUS AND PREVENTIVE MEASUREMENTS FOR CANCER PATIENTS.....	213-217

MORE ON DEEP HEMATOMAS IN PATIENTS WITH COVID-19: CASE SERIES

Lipatov K.V¹, Komarova E.A¹, Solov'eva E.I¹, Kazantsev A.D¹, Gorbacheva I.V¹, Sotnikov D.N¹, Voinov M.A¹, Avdienko E.V¹, Shevchuk A.S¹, Sarkisyan I.P¹.

1Federal State Autonomous Educational Institution of Higher Education I.M. Sechenov First Moscow State Medical University of the Ministry of Health of the Russian Federation (Sechenov University), Moscow, 119991, Moscow, Trubetskaya str., 8, p.2, Russian Federation.

Abstract.

Background: Despite the fact that the COVID-19 epidemic has already ended, there is no clear answer to the question - what is the nature of the imbalance in the hemocoagulation system, and which phenomena prevail - thrombosis or hemorrhage? More and more new works appear describing the occurrence of deep, extensive hematomas in patients with COVID-19. However, this experience requires further discussion and understanding.

Case Description: From October 2020 to January 2021, 7 (2,1% among all hospitalized with COVID-19 in this period) patients with developed hematomas were observed at the COVID-19 hospital. All of them, taking into account their severe condition (according to the SOFA scale) and the high risk of thromboembolic complications (according to the Caprini scale), received a therapeutic dose of calcium nadroparin. Superficial hematomas were observed in 2 patients, and deep hematomas – in 5 patients. Their volume was up to 340 ml. Instrumental diagnostics included ultrasound and computed tomography. The most difficult were hematomas in the area of musculus iliopsoas. The median time of the onset of hematomas from the start of treatment was 7 days (interquartile range [IQR], 4-9 days). The indication for puncture was a hematoma volume of more than 100 ml, as well as a suspicion of suppuration. Analysis of coagulograms revealed signs of hypercoagulation and imbalance in the blood coagulation system. In 3 patients, the D-dimer level exceeded 4000 ng/ml. They were fatal, and autopsy revealed multiple thrombosis of the small branches of the pulmonary artery. Deep vein thrombosis of the lower extremities was not detected. The mortality rate among patients with developed hematomas was 42.9%, and the average mortality rate for this hospital in the indicated period of time was 7.1%.

Conclusions: An imbalance in which, along with thrombotic complications, hemorrhagic manifestations are observed, is one of the features of COVID-19. The deep hematomas developing at the same time are poorly understood and sharply complicate the course of the infection.

Key words. COVID-19, deep hematomas, musculus iliopsoas, suppuration, case series.

Introduction.

The steady increase in the number of cases of the new coronavirus infection (SARS-Cov-2) is accompanied by studies studying the pathogenesis and complications of this pathology. It is known that the disease is based on disorders of the immune response, accompanied by overproduction of pro-inflammatory cytokines [1-4]. The developing "cytokine storm" is considered as the pathophysiological basis of damage to the capillary endothelium and vascular thrombosis of the microvasculature [1-5]. The result is organ dysfunction, with the lungs in first

place among target organs. Progressive respiratory failure in severe disease is one of the main causes of death [1-4].

The high risks of thrombotic complications characteristic of COVID-19 have become the basis for the inclusion of anticoagulant therapy in the complex of treatment measures [6-9]. In patients with a severe course of new coronavirus infection, preference is given to the administration of low molecular weight heparins [2,6,7,10]. With moderate or mild severity of the disease, oral direct anticoagulants (rivaroxaban, dabigatran, apixaban) are more often used on an outpatient basis [8,10-12]. One of the most controversial is the question of choosing between prophylactic and therapeutic doses of drugs [7,8,10,11]. Most of the authors note the need to prescribe therapeutic doses of anticoagulants in severe disease and in groups with high thrombosis and thromboembolic complications. In other cases, prophylactic dosages are more often prescribed [6,8,11,12].

Anticoagulant therapy is associated with a certain, albeit insignificant, risk of hemorrhagic complications, including hematomas of various localization. Their frequency in the appointment of low molecular weight heparins, according to various sources, ranged from 0.1% to 2.2% [13-16]. Extensive hematomas, which determine the need for surgical interventions, were extremely rare [1,2,9]. Studies have shown that the frequency of bleeding with the use of therapeutic doses of these drugs was only slightly higher than with prophylactic ones – 3% versus 1.7% [8].

Analysis of publications showed that with COVID-19, the incidence of bleeding and hematomas is higher than in other patients receiving low molecular weight heparins [2,5,10,13]. It has been reported that with a new coronavirus infection, along with a high risk of thrombosis, there is a pronounced imbalance in the hemocoagulation system, both among plasma and platelet factors [1]. This was confirmed during autopsies, when not only signs of thrombosis were found in the vessels of the microvasculature, but also hemorrhagic manifestations [1]. The occurrence of hematomas was more often noted in the severe course of COVID-19 and was, as a rule, spontaneous. The factor of trauma or medical manipulation was absent or was minimal [3]. Among the risk factors for such complications are advanced age, diabetes mellitus, systemic collagenoses, coagulopathy [3,7,17].

All hematomas in patients with COVID-19 are divided into superficial and deep. Superficial hematomas were usually located in the subcutaneous fatty tissue of the trunk and extremities [3]. They were not a problem, and anticoagulant therapy could be continued [3,18]. Deep hematomas were presented as intermuscular or intramuscular, or were located in deep cellular spaces, for example, in the retroperitoneal tissue [1,2,5,19]. The intracranial arrangement of hematomas has also been described [19,20]. And if intracranial hematomas

were in the competence of neurosurgeons, then in the case of intermuscular and retroperitoneal hematomas, general surgeons were usually involved in treatment.

Extensive hematomas in the iliopsoas muscle are especially dangerous [1,2,5,9]. Musculus iliopsoas is one of the most powerful muscles in the human body and provides, in addition to flexion of the lower limb in the hip joint, static maintenance of the balance of the body. In some cases, this can be associated with overstrain and tears, which poses a risk of bleeding and the formation of an extensive hematoma. Published data on such hematomas, which in size significantly exceeded the volume of the muscle itself [2,5]. The formation of these hematomas could also be facilitated by a hacking cough during coronavirus infection [1]. Retroperitoneal hematomas, including in the area of m. iliopsoas presented certain diagnostic difficulties and also influenced the prognosis of the disease. Thus, the risk of death in COVID-19, complicated by a hematoma in the iliopsoas muscle, increased to 50% [1].

Clinical diagnosis of deep massive hematomas was based on pain and symptoms of existing or ongoing bleeding: tachycardia, hypotension, drop in hemoglobin levels [1,2,5,7]. If deep hematomas are suspected, ultrasound, as well as computed tomography and magnetic resonance imaging, have become the methods of choice [1,2,5,7]. The presence of extensive hematoma in the area of m. iliopsoas with signs of ongoing bleeding served as an indication for performing direct angiography of the vessels of the retroperitoneal space [1,2]. Selective X-ray endovascular embolization of a bleeding artery made it possible to achieve stable hemostasis [1,2]. This method has significant advantages over open surgery, which is especially important for hemodynamically unstable patients with COVID-19 receiving high doses of anticoagulants [1,2]. CT performed in dynamics revealed a significant reduction in hematoma in size, which made it possible to do without puncture and drainage [2]. Extensive hematomas of the soft tissues of the extremities and trunk, according to some authors, require puncture treatment or drainage [3,7]. The presence of extensive hematomas of various localization served as the basis for the termination of anticoagulant therapy [1,2,18].

Aim of the study: to analyze the occurrence of deep hematomas in patients with COVID-19, their relationship with the severity of the infection, prognosis of the disease, changes in coagulograms, as well as approaches to diagnosis and treatment.

Case Presentation.

In the period from October 2020 to January 2021, among inpatients with a new coronavirus infection under the supervision of a surgeon, there were 7 patients with developed hematomas of various localization. All patients were diagnosed with bilateral polysegmental viral pneumonia. The severity of the patient's condition and the severity of organ dysfunction were assessed using the SOFA (Sequential Organ Failure Assessment) scale. Elderly persons predominated (Table 1). The diagnosis of the new coronavirus infection was confirmed by a positive PCR test and tests for IgG, IgM antibodies to SARS-CoV-2, as well as the results of computed tomography (CT) of the chest organs.

The risk of thrombosis and thromboembolic complications was assessed using the Caprini scale [12,21,22]. The scores 1-2 corresponded to low risk, 3-4 – medium, and ≥ 5 – high.

Complex treatment of all patients included the appointment of low molecular weight heparins (calcium nadroparin). At high risk (on the Caprini scale), therapeutic doses of anticoagulant were prescribed. The state of the blood coagulation system was monitored by repeated studies of coagulograms, including such parameters as: D-dimer, Activated Partial Thromboplastin Time (APTT), Prothrombin time (PT), International normalized ratio (INR), Antithrombin III (AT III), Fibrinogen, Platelets (PLT). We analyzed the initial data of coagulograms upon admission of patients to the hospital, as well as their dynamics by the time of detection of hematomas. Among the parameters of the coagulogram, the greatest importance in the diagnosis of thrombosis and thromboembolic complications was given to D-dimer [12,21,22]. For D-dimer values ≥ 2000 ng/ml, ultrasonic duplex angioscanning of the veins of the lower extremities was performed.

Diagnosis of developed hematomas was based on patients' complaints, as well as on the results of general clinical and instrumental examination: ultrasound and computed tomography. Superficial hematomas (2 patients) were located in the subcutaneous fatty tissue, either intramuscularly or intermuscularly (Table 1). Deep (5 patients) – intramuscularly or intermuscularly: 2 – in the region of the iliopsoas muscle, 2 – the anterior abdominal wall, 1 – thigh. Hematoma volumes varied. The greatest volume was observed with their intramuscular localization (Table 1).

For small subcutaneous hematomas, anticoagulant therapy with low molecular weight heparins was continued, in other cases it was stopped.

All procedures performed in this study were in accordance with the ethical standards of the institutional and/or national research committee(s) and with the Helsinki Declaration (as revised in 2013). Written informed consent for publication of this case series and accompanying images was obtained from the patients or their relatives.

Discussion.

The general condition of all patients was assessed as serious. The degree of organ dysfunction ranged from 13 to 25 points on the SOFA scale, predicting an extremely high risk of death in 3 cases (patients B, D, G – Table 1). Assessment of the risk of thrombosis and thromboembolic complications according to the Caprini scale showed that in all cases it was equal to or exceeded 5 points, reaching a maximum of 8 points (Table 2).

Ultrasound examination made it possible to visualize hematomas in all cases, however, more detailed characteristics were provided by computed tomography with contrast enhancement, which became the method of choice for deep hematomas (Figures 1, 2A, 2B, 3A and 3B). Subcutaneous hematomas ($n = 2$) had a relatively small volume (26 and 50 ml for the liquid part). Intramuscular and intermuscular hematomas ($n = 5$) only in the liquid part occupied a volume from 170 to 340 ml (on average – 268 ml). However, during instrumental examination, in addition to the liquid part, a significant infiltration zone of the surrounding muscle was revealed, probably associated with its imbibition by blood. Deep hematomas in the iliopsoas muscle ($n = 2$) were characterized by the largest volume, manifested by pain in the lumbar region.

Table 1. General characteristics of patients with hematomas associated with COVID-19.

A patient/ SOFA score in hospitalization	Localization	Volume, ml†	Age, years	Time of hematoma detection, days‡	Structure	Perifocal infiltration	Research methods	Suppuration suspected	Puncture, evacuation of hematoma	Suppuration of hematoma	Drainage	Reduction of hematoma over time	Cancellation of anticoagulants	COVID-19 outcome
A/13	Musculus iliopsoas dext.	300	74	2	heterogeneous	+++	CT, ULTRASOUND	+++	yes	no	no	yes	yes	recovery
B/25	Musculus iliopsoas dext.	320	86	8	heterogeneous	+++	CT, ULTRASOUND	+++	yes	no	no	yes	yes	lethal
C/12	Lower leg (subcutaneous)	26	65	11	heterogeneous	+	ULTRASOUND	+	no	no	no	no	no	recovery
D/23	Forearm, hand (subcutaneously)	50	83	14	homogeneous	+	ULTRASOUND	+	no	no	no	yes	no	lethal
E/15	Anterior abdominal wall (intramuscularly)	340	82	4	heterogeneous	+++	CT, ULTRASOUND	++	yes	no	no	yes	yes	recovery
F/14	Thigh (intermuscular)	170	67	18	heterogeneous	++	ULTRASOUND	++	yes	no	no	yes	yes	recovery
G/24	Anterior abdominal wall (intramuscularly)	210	80	6	heterogeneous	+++	ULTRASOUND	+++	yes	yes	yes	no	yes	lethal

«+++», a pronounced factor; «++», moderately pronounced; «+», mild; «†», the volume of the liquid part of the hematoma; «‡», time elapsed from the appointment of anticoagulants to the detection of hematoma.

Table 2. Characteristics of the main parameters of the hemocoagulation system and Carpini-score in patients.

Indicators	Reference values	Patients													
		A.		B.		C.		D.		E.		F.		G.	
		Terms of hematoma formation from the beginning of anticoagulant therapy (days)													
		2		8		11		14		4		18		6	
		Initially	Hematoma	Initially	Hematoma	Initially	Hematoma	Initially	Hematoma	Initially	Hematoma	Initially	Hematoma	Initially	Hematoma
D-dimer, ng/ml	0-255	838	955	4625	378	Initially	Hematoma	1430	8442	1362	1125	389	1108	8752	10000
APTT, sec	24,0–38,0	23,7	39,0	34,0	29	190	138	29,0	28,0	28	34,0	40,7	26,4	53,8	23,0
PT, sec	9,4–11,0	10,4	11,0	10,3	12,1	27,0	28,7	15,9	15,4	9,9	9,3	11,7	12,0	12,7	11,3
INR	0,70–1,30	1,02	1,09	1,01	1,21	11,3	13,6	1,35	1,57	0,97	0,90	1,16	1,02	1,28	1,12
Fibrinogen, g/l	2,20–4,50	4,20	3,13	5,97	2,20	1,12	1,16	4,1	2,78	3,23	2,49	4,84	3,25	6,56	3,01
AT III, %	83,0–128,0	84	89	98	102	4,95	2,11	55	76,4	86,5	90,2	92,1	140	74,0	79
PLT, 10 ⁹ /l	150–400	174	264	130	191	89	88,1	142	130	135	117	157	187	190	294
Carpini score		6		6		8		7		7		6		8	

APTT, Activated Partial Thromboplastin Time; PT, Prothrombin time; INR, International normalized ratio; AT III, Antithrombin III; PLT, Platelets.

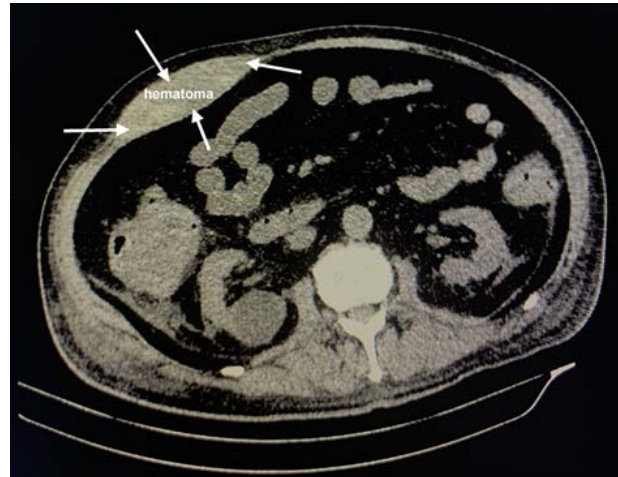

Figure 1. CT-picture (without intravenous contrasting) of hematoma of the right rectus abdominis muscle.

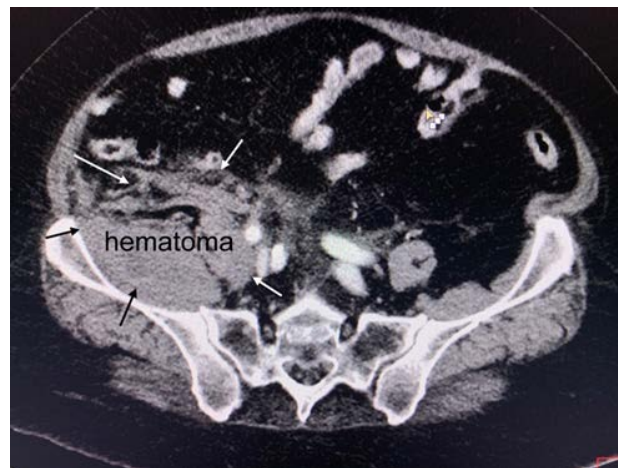

Figure 2A. CT scan (without intravenous contrasting) of the right iliopsoas muscle hematoma. The thickening and heaviness of the structure of m. Iliopsoas, pronounced the imbibition of her blood.

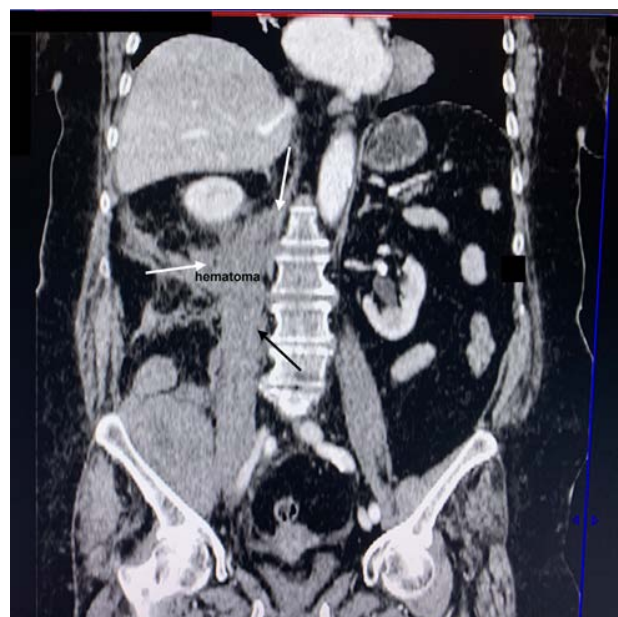

Figure 2B. 2-D reconstruction.

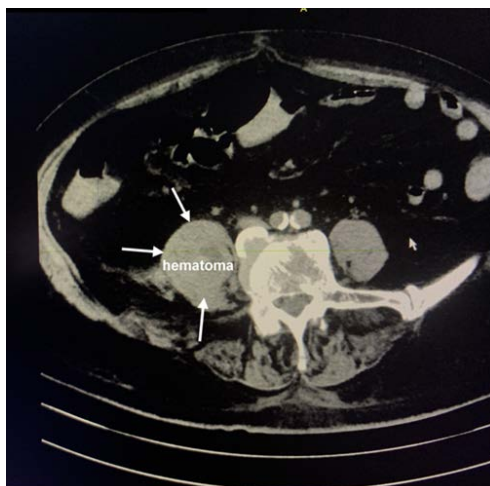


Figure 3A. CT picture (with intravenous contrast) of hematoma of the right iliopsoas muscle: there is an increase in the size of m. iliopsoas, a hypodense area 23 * 21 * 50 mm is visualized at the L4-L5 level.

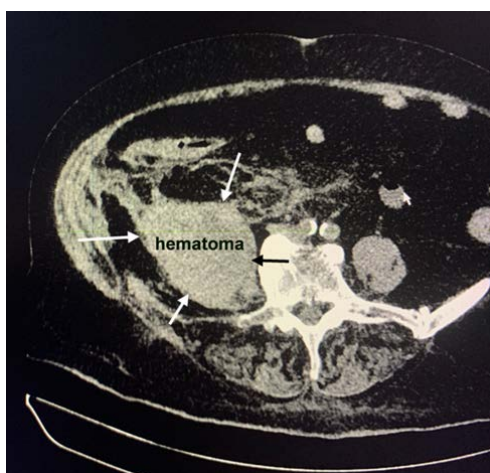


Figure 3B. CT picture (with intravenous contrast) of hematoma of the right iliopsoas muscle in dynamics (after a day): against the background of an increase in size and heterogeneity of the structure of m. iliopsoas, an increase in the size of the hematoma to 55 * 45 * 130 mm is noted. After the introduction of a contrast agent, areas of local accumulation of a contrast agent are determined in the muscle structure, which may indicate extravasation.

In 6 cases, on the basis of the heterogeneity of the contents of the hematomas, suppuration was suspected. Two main indications for performing puncture of a hematoma (under ultrasound control) have been formulated: 1) suspicion of suppuration and 2) sizes of more than 100 ml (for the liquid component). In the presented observations, 5 patients (all with deep hematomas) underwent puncture of hematomas with evacuation of their liquid part. Of these, suppuration was detected in 1 case. *Staphylococcus aureus* was isolated. Drainage has been carried out. All patients received antimicrobial treatment with 4th generation drugs.

A study of the factors of the blood coagulation system in patients revealed a picture of hypercoagulability with a sharp increase in the concentration of D-dimer, which is considered characteristic of COVID-19 [20,23]. No reliable data were obtained on a decrease in the concentration of D-dimer during inpatient treatment with the use of therapeutic doses of nadroparin calcium. In three patients (G, B, D), the D-dimer level exceeded 4000 ng/ml. The ultrasound duplex angioscanning of the deep veins of the lower extremities did not reveal any signs of thrombosis. All three cases were fatal. Autopsy showed a

severe lesion of the lung tissue with multiple thrombosis of the small branches of the pulmonary artery. At the same time, deep vein thrombosis of the lower extremities was not detected as a factor of possible thromboembolism (Figure 4).

Analyzing the data in Table 2, a pronounced imbalance in the blood coagulation system can be noted. Thrombocytopenia of varying severity occurred in 3 cases. This is also typical for coronavirus infection and may also be a consequence of therapy with low molecular weight heparins [16,22,23]. In such cases, it would be preferable to use fondaparinux sodium, which is not characterized by such a complication [20,22,23]. It should be noted that a sharp drop in the number of platelets during treatment (up to $9 \times 10^9/l$) was observed in only one patient (S.). However, it was he who was diagnosed with the smallest of all hematomas with localization in the subcutaneous fatty tissue (Tables 1 and 2). Thus, despite the formation of hematomas in patients, there were no signs of hypocoagulation according to the studied parameters of coagulograms.

A limitation of this case series includes the lack of follow up with the patients to better understand any long-term implications of this mechanism of pathology.

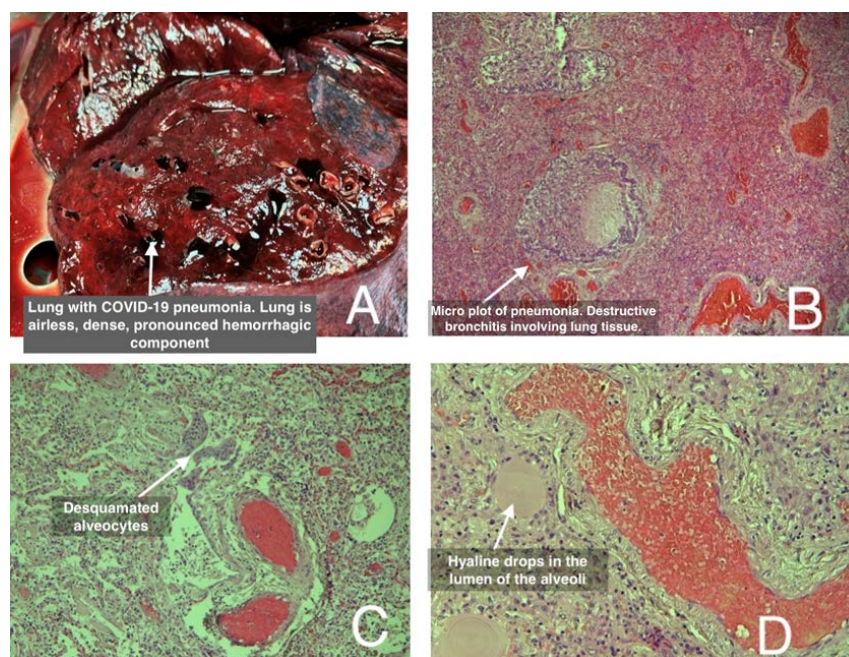


Figure 4. Morphological examination of tissues removed during surgical treatment. (A) macroslide: lung is grayish-brown, airless, with a granular appearance in the section. (B) microslide x5: hematoxylin-eosin stain, overview micrograph of pneumonia in COVID-19. Small bronchi with signs of inflammation, partial lysis of the walls and the spread of the inflammatory process to the lung parenchyma. There is an inflammatory infiltrate impregnated with fibrin in the lumen of the bronchioles. Severe dyscirculatory disorders in the tissue of the affected lung. Inflammatory infiltrate in the lung tissue is rich in fibrin. (C) microslide x10: hematoxylin-eosin stain, micrograph of pneumonia in COVID-19. Desquamated alveocytes in the focus of pneumonia, the formation of hyaline membranes. Pronounced fibrinous component. (D) microslide x20: hematoxylin-eosin stain, micrograph of pneumonia in COVID-19. Stasis in the vessels of the microvasculature. Hyaline drops in the lumen of the alveoli.

Conclusion.

The occurrence of hematomas in patients with COVID-19 was not a direct factor in determining the severity of the course of the disease. However, the mortality rate with the development of this complication was 42.9%, significantly exceeding the average mortality rate among the patients of this hospital – 7.1%. Thus, the detection of hematomas has become a kind of marker of the severity of the condition and a high probability of death.

An imbalance in the hemocoagulation system, when hemorrhagic complications develop along with hypercoagulation, is a feature of the new coronavirus infection. The most difficult are hematomas in the iliopsoas muscle. Their etiopathogenesis remains a subject of debate, and treatment tactics are not clearly defined. The potential risk of suppuration of such hematomas is also significant, which can become a critical factor in patients with severe viral infection. All this determines the need for further research.

Declaration of Conflicting Interests.

The authors declare no conflicts of interest regarding the publication of this paper.

Statement of Funding.

The author(s) received no financial support for the research, authorship, and/or publication of this article.

Ethical Statement.

The authors are accountable for all aspects of the work in ensuring that questions related to the accuracy or integrity of any part of the work are appropriately investigated and resolved.

All procedures performed in this study were in accordance with the ethical standards of the institutional and/or national research committee(s) and with the Helsinki Declaration (as revised in 2013). Written informed consent was obtained from the patient for the publication of this case report and accompanying images. A copy of the written consent is available for review by the editorial office of this journal.

REFERENCES

1. Conti CB, Henchi S, Coppeta GP, et al. Bleeding in COVID-19 severe pneumonia: The other side of abnormal coagulation pattern?. *Eur J Intern Med.* 2020;77:147-149.
2. Patel I, Akoluk A, Douedi S, et al. Life-Threatening Psoas Hematoma due to Retroperitoneal Hemorrhage in a COVID-19 Patient on Enoxaparin Treated With Arterial Embolization: A Case Report. *J Clin Med Res.* 2020;12:458-461.
3. Mattioli M, Benfaremo D, Fustini E, et al. Atypical Spontaneous Hematomas in a Patient with Severe Coronavirus Disease 2019 (COVID-19). *Semin Thromb Hemost.* 2020;46:856-858.
4. Tang N, Li D, Wang X, et al. Abnormal coagulation parameters are associated with poor prognosis in patients with novel coronavirus pneumonia. *J Thromb Haemost.* 2020;18:844-847.
5. Mazzitelli M, Serapide F, Tassone B, et al. Spontaneous and Severe Haematomas in Patients with COVID-19 on Low-Molecular-Weight Heparin for Paroxysmal Atrial Fibrillation. *Mediterr J Hematol Infect Dis.* 2020;12:e2020054.
6. Dorgalaleh A. Bleeding and Bleeding Risk in COVID-19. *Semin Thromb Hemost.* 2020;46:815-818.

7. Mechineni A, Nanavati S, Solis RA, et al. Dilemma of systemic anticoagulation: a COVID-19 patient with spontaneous chest wall hematoma. *Chest*. 2020;158:A409.
8. Nakamura H, Ouchi G, Miyagi K, et al. Case Report: Iliopsoas Hematoma during the Clinical Course of Severe COVID-19 in Two Male Patients. *Am J Trop Med Hyg*. 2021;104:1018-1021.
9. Morovic M. Spontaneous Muscle Hematoma in Patients with COVID-19: Experience of 3 Cases. *Ann Clin Med Case Rep*. 2021;6:1-5.
10. Cattaneo M, Bertinato EM, Birocchi S, et al. Pulmonary Embolism or Pulmonary Thrombosis in COVID-19? Is the Recommendation to Use High-Dose Heparin for Thromboprophylaxis Justified?. *Thromb Haemost*. 2020;120:1230-1232.
11. Kollias A, Kyriakoulis KG, Dimakakos E, et al. Thromboembolic risk and anticoagulant therapy in COVID-19 patients: emerging evidence and call for action. *Br J Haematol*. 2020;189:846-847.
12. Thachil J, Tang N, Gando S, et al. ISTH interim guidance on recognition and management of coagulopathy in COVID-19. *J Thromb Haemost*. 2020;18:1023-1026.
13. Agnelli G, Buller HR, Cohen A, et al. Oral apixaban for the treatment of acute venous thromboembolism. *N Engl J Med*. 2013;369:799-808.
14. Kearon C, Akl EA, Comerota AJ, et al. Antithrombotic therapy for VTE disease: Antithrombotic Therapy and Prevention of Thrombosis, 9th ed: American College of Chest Physicians Evidence-Based Clinical Practice Guidelines [published correction appears in *Chest*. 2012;142:1698-1704]. *Chest*. 2012;141:e419S-e496S.
15. Schulman S, Kearon C; Subcommittee on Control of Anticoagulation of the Scientific and Standardization Committee of the International Society on Thrombosis and Haemostasis. Definition of major bleeding in clinical investigations of antihemostatic medicinal products in non-surgical patients. *J Thromb Haemost*. 2005;3:692-694.
16. Sottilotto G, Mangano C, Basile R, et al. Iliopsoas hematoma in patients with COVID-19 on low-molecular-weight heparin treatment. *SAGE Open Med Case Rep*. 2021;9:2050313X211016991.
17. Zhou F, Yu T, Du R, et al. Clinical course and risk factors for mortality of adult inpatients with COVID-19 in Wuhan, China: a retrospective cohort study [published correction appears in *Lancet*]. 2020;395:1038.
18. Jaffer IH, Weitz JJ. Antithrombotic drugs. In: Hoffman R.H., Benz E.J., Silberstein L.E., Weitz H.H, Ji A., Salama M.E., Abutalib S.A. (eds) *Hematology, basic principles and practice*, 7th edn. Saunders-Elsevier, Philadelphia, 2018:2168-2188.
19. Altschul DJ, Unda SR, de La Garza Ramos R, et al. Hemorrhagic presentations of COVID-19: Risk factors for mortality. *Clin Neurol Neurosurg*. 2020;198:106112.
20. Abate V, Casoria A, Rendina D, et al. Spontaneous Muscle Hematoma in Patients with COVID-19: A Systematic Literature Review with Description of an Additional Case Series. *Semin Thromb Hemost*. 2022;48:100-108.
21. Benhamou D, Keita H, Ducloy-Bouthors AS; Obstetric Anaesthesia and Critical Care Club Working Group. Coagulation

changes and thromboembolic risk in COVID-19 obstetric patients. *Anaesth Crit Care Pain Med*. 2020;39:351-353.

22. Betoule A, Martinet C, Gasperini G, et al. Diagnosis of venous and arterial thromboembolic events in COVID-19 virus-infected patients. *J Thromb Thrombolysis*. 2020;50:302-304.

23. Ito Y, Awano N, Uchiyama F, et al. Spontaneous Muscle Hematoma in Japanese Patients with Severe COVID-19 Treated with Unfractionated Heparin: Two Case Reports. *Intern Med*. 2021;60:3503-3506.

РЕЗЮМЕ

К вопросу о глубоких гематомах у пациентов с COVID-19: серия случаев

Липатов К.В¹, Комарова Е.А¹, Соловьева Е.И¹, Казанцев А.Д¹, Горбачева И.В¹, Сотников Д.Н¹, Войнов М.А¹, Авдиенко Е.В¹, Шевчук А.С¹, Саркисян И.П¹

¹ФГАОУ ВО Первый Московский государственный медицинский университет имени И.М. Сеченова Минздрава России (Сеченовский Университет), 119991, г. Москва, ул. Трубецкая, 8, стр. 2, Россия.

Введение: несмотря на то, что эпидемия COVID-19 уже завершилась, нет однозначного ответа на вопрос – какова природа дисбаланса в системе гемокоагуляции и какие явления преобладают – тромбоз или кровоизлияние? Появляется все больше новых работ, описывающих возникновение глубоких, обширных гематом у пациентов с COVID-19. Однако этот опыт требует дальнейшего обсуждения и осмысления.

Описание случая: с октября 2020 по январь 2021 г. в COVID-19 стационаре наблюдали 7 (2,1% среди всех госпитализированных с COVID-19 за этот период) пациентов с развившимися гематомами. Все они с учетом тяжелого состояния (по шкале SOFA) и высокого риска тромбоэмболических осложнений (по шкале Caprini) получали надрупарин кальция в лечебной дозе. Поверхностные гематомы отмечены у 2 пациентов, глубокие – у 5 заболевших. Их объем составлял до 340 мл. Инструментальная диагностика включала ультразвуковое исследование и компьютерную томографию. Наиболее тяжело протекали внутри- и межмышечные гематомы в области musculus iliopsoas.

Средний срок возникновения гематом от начала лечения составил $7,6 \pm 2,4$ (M $\pm\sigma$) дней. Показанием для пункции стал объем гематом более 100 мл, а также подозрение на нагноение. Анализ коагулограмм выявил признаки гиперкоагуляции и дисбаланса в свертывающей системе крови. У 3-х пациентов уровень D-dimer превысил 4000 ng/ml. У них наблюдался летальный исход, а аутопсия выявила множественные тромбозы мелких ветвей легочной артерии. Тромбоз глубоких вен нижних конечностей обнаружен не был. Летальность среди пациентов с развившимися гематомами составила 42,9%, а средняя летальность по данному лечебному учреждению в указанный промежуток времени – 7,1%.

Заключение: дисбаланс, при котором наряду с тромботическими осложнениями наблюдаются геморрагические проявления, является одной из

особенностей COVID-19. Развивающиеся при этом глубокие гематомы мало изучены и резко осложняют течение инфекции.

Ключевые слова: COVID-19; глубокие гематомы; musculus iliopsoas; нагноение; серия случаев.

შეჯამება

მეტი ღრმა ჰემატომების შესახებ COVID-19-ით დაავადებულ პაციენტებში: შემთხვევების სერია

Lipatov K.V¹, Komarova E.A¹, Solov'eva E.I¹, Kazantsev A.D¹, Gorbacheva I.V¹, Sotnikov D.N¹, Voinov M.A¹, Avdienko E.V¹, Shevchuk A.S¹, Sarkisyan I.P¹

¹უმაღლესი განათლების ფედერალური სახელმწიფო ავტონომიური საგანმანათლებლო დაწესებულება ი.მ. სეჩენოვი რუსეთის ფედერაციის ჯანდაცვის სამინისტროს პირველი მოსკოვის სახელმწიფო სამედიცინო უნივერსიტეტი (სეჩენოვის უნივერსიტეტი), მოსკოვი, რუსეთის ფედერაცია, 119991, მოსკოვი, ტრუბეცკაიას ქ., 8, გვ.2, ელ.

აბსტრაქტი.

ჩანაწერი: მიუხედავად იმისა, რომ COVID-19-ის ეპიდემია უკვე დასრულდა, არ არსებობს მკაფიო პასუხი კითხვაზე - რა არის ჰემოკოაგულაციის სისტემაში დისბალანსის ბუნება და რომელი ფენომენები ჭარბობს - თრომბოზი თუ სისხლჩაქცევა? სულ უფრო მეტი ახალი ნამუშევარი ჩნდება, რომლებიც აღწერს ღრმა, ვრცელი ჰემატომების გაჩენას COVID-19-ით დაავადებულ პაციენტებში. თუმცა, ეს გამოცდილება მოითხოვს შემდგომ განხილვას და გაგებას.

შემთხვევის აღწერა: 2020 წლის ოქტომბრიდან 2021 წლის იანვრამდე, COVID-19 საავადმყოფოში დაფიქსირდა 7 (2,1% ამ პერიოდში COVID-19-ით ჰოსპიტალიზირებული ყველა ჰოსპიტალში) განვითარებული ჰემატომის

მქონე პაციენტი. ყველა მათგანმა მძიმე მდგომარეობის (SOFA-ს სკალის მიხედვით) და თრომბოემბოლიური გართულებების მაღალი რისკის გათვალისწინებით (კაპრინის სკალის მიხედვით) მიიღო კალციუმის ნადროპარინის თერაპიული დოზა. ზედაპირული ჰემატომები დაფიქსირდა 2 პაციენტში და ღრმა ჰემატომები - 5 პაციენტში. მათი მოცულობა 340 მლ-მდე იყო. ინსტრუმენტული დიაგნოსტიკა მოიცავდა ულტრაბგერას და კომპიუტერულ ტომოგრაფიას. ყველაზე რთული იყო ჰემატომები musculus iliopsoas-ის მიდამოში. ჰემატომების გაჩენის მედიანური დრო მკურნალობის დაწყებიდან იყო 7 დღე (კვარტლთაშორისი დიაპაზონი [IQR], 4-9 დღე). პუნქციის ჩვენება იყო ჰემატომის მოცულობა 100 მლ-ზე მეტი, ასევე სუპურაციის ეჭვი. კოაგულოგრამების ანალიზმა გამოავლინა ჰიპერკოაგულაციის ნიშნები და დისბალანსი სისხლის კოაგულაციის სისტემაში. 3 პაციენტში D-დიმერის დონემ გადააჭარბა 4000 ნგ/მლ. ისინი ფატალური იყო და აუტოფსიამ გამოავლინა ფილტვის არტერიის მცირე ტოტების მრავლობითი თრომბოზი. ქვედა კიდურების ღრმა ვენების თრომბოზი არ გამოვლენილა. განვითარებული ჰემატომის მქონე პაციენტებში სიკვდილიანობის მაჩვენებელი იყო 42,9%, ხოლო საშუალო სიკვდილიანობა ამ საავადმყოფოში მითითებულ პერიოდში 7,1%.

დასკვნები: დისბალანსი, რომელშიც თრომბოზულ გართულებებთან ერთად, შეინიშნება ჰემორაგიული გამოვლინებები, არის COVID-19-ის ერთ-ერთი მახასიათებელი. ამავე დროს განვითარებული ღრმა ჰემატომები ცუდად არის გასაგები და მკვეთრად აართულებს ინფექციის მიმდინარეობას.

საკვანძო სიტყვები: COVID-19; ღრმა ჰემატომები; musculus iliopsoas; სუპურაცია; საქმეების სერია.